

**Surgical treatment of  
thoracic trauma depending  
on the affected intrathoracic  
organs**

**Χειρουργική αντιμετώπιση  
θωρακικού τραύματος  
ανάλογα με την  
τοπογραφική προσβολή των  
ενδοθωρακικών οργάνων**

**Michael Klimatsidas  
Consultant Thoracic Surgeon  
Glasgow – Scotland  
Thessaloniki - Greece**

**The Athens Crossroad**  
**8-10 November 2018**  
Zappeion Megaron Hall, Athens



# Statistics

- Thoracic trauma accounts for 20-25% deaths due to injury in US
- 16,000 deaths per year due to chest injury
- Rate of thoracic injuries 12 per million population per day (~30/day in Miami- Dade County)
- About 50% fatalities of MVA have sustained some chest injury
- Ratio penetrating/non penetrating *variable* usually about 75-85% blunt injuries

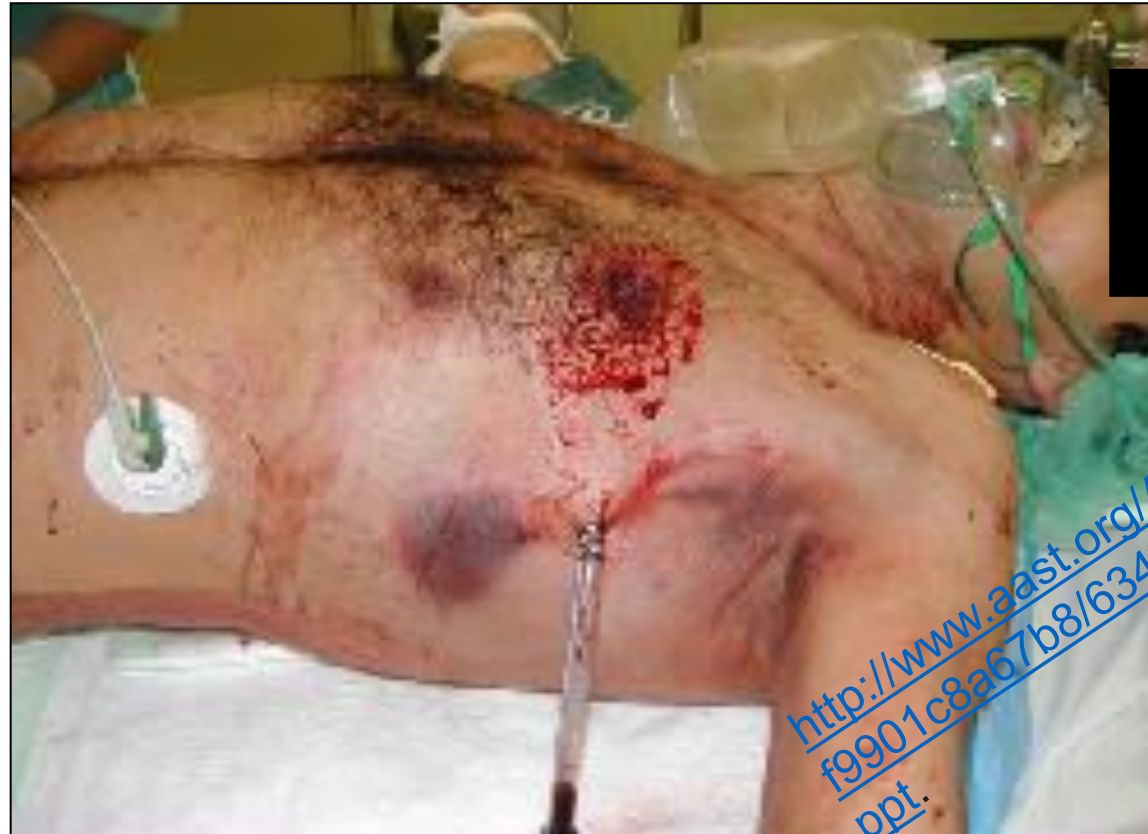The Athens Crossroad

8-10 November 2018

Zappeion Megaron Hall, Athens



# Immediate Life Threatening Thoracic Injuries: Primary Survey



The Athens Crossroad

8-10 November 2018

Zappeion Megaron Hall, Athens



# Management – Primary Survey

Always consider mechanical factors

- Airway/spinal stabilization
  - Trachea, bronchial disruption
- Breathing
  - Chest wall integrity, pneumothorax, flail
  - Pulmonary contusions, O<sub>2</sub> diffusion block
- Circulation
  - Tamponade, hemothorax, tension pneumothorax
  - Cardiac, great vessel injury

The Athens Crossroad

8-10 November 2018

Zappeion Megaron Hall, Athens



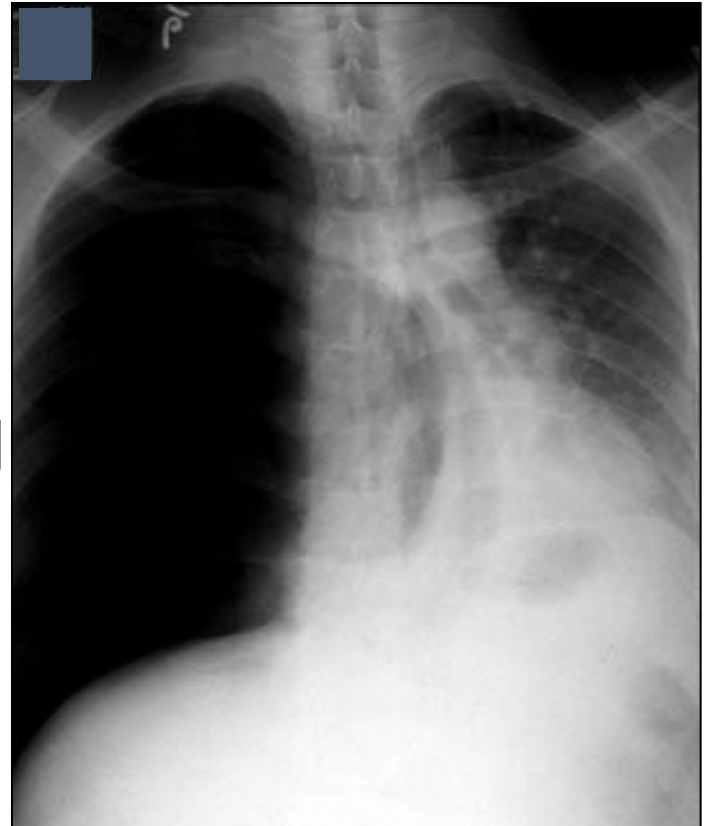
*Immediate Life Threatening Thoracic Injuries:*  
***Cardiac Tamponade***

- Pathophysiology – intra-pericardial pressure exceeds filling pressure of right heart
- Impairs venous return and cardiac filling leading to hypotension, narrow pulse pressure, PEA
- “Beck’s Triad” - hypotension, neck vein distension, distant/absent heart tones
- Signs and symptoms masked by hypovolemia
- Treat with immediate volume replacement to ↑ CVP, pericardial decompression



# Immediate Life Threatening Thoracic Injuries: Tension Pneumothorax

- Suspect with any injury
- High intra-thoracic, extra-pulmonary pressure
- Absent breath sounds, shift of trachea, hypotension
- Can be worsened with intubation and + pressure
- Treat symptoms → immediate decompression



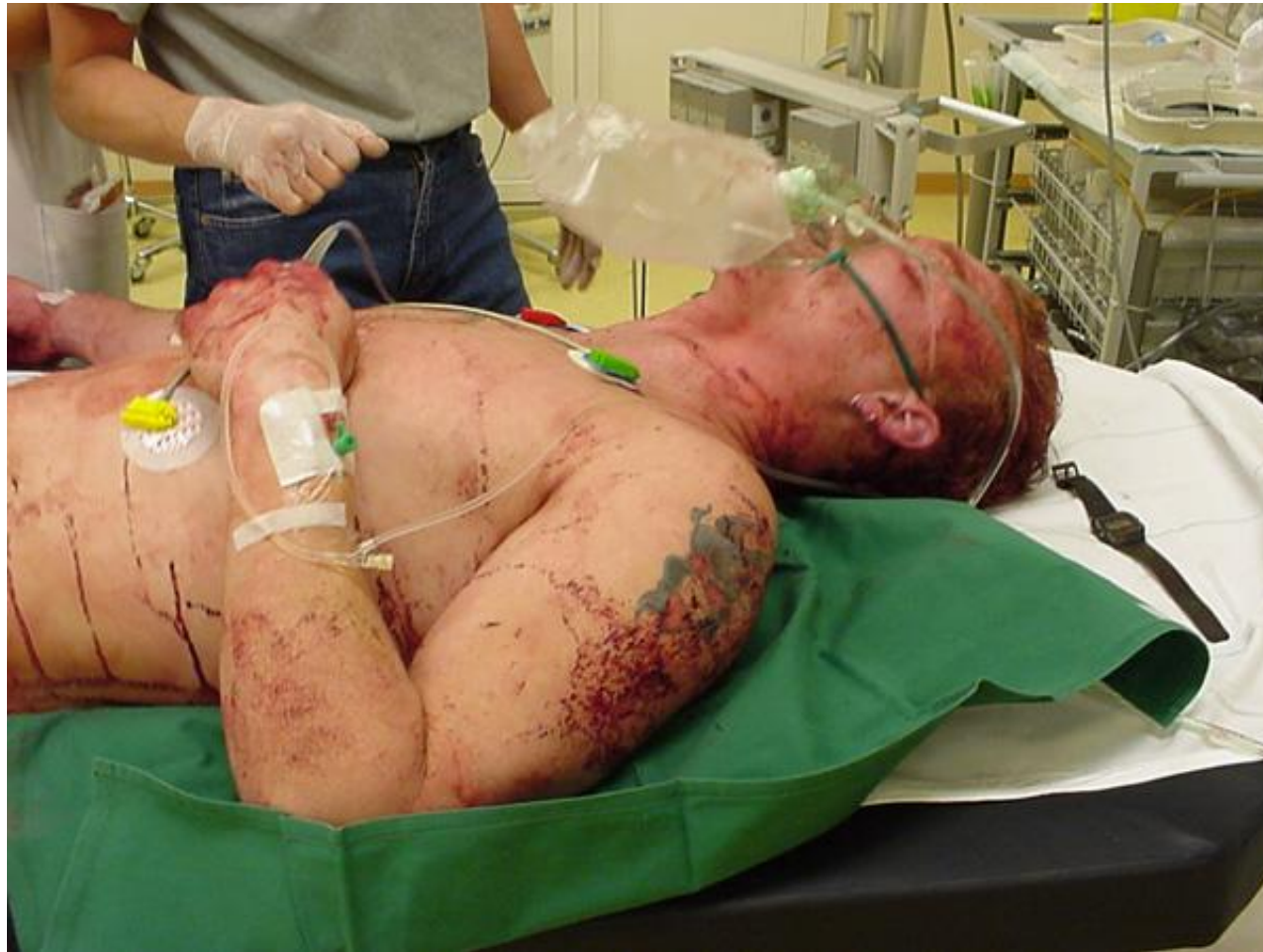The Athens Crossroad

8-10 November 2018

Zappeion Megaron Hall, Athens



# Exposure



Author unknown,

<http://www.trauma.org/index.php/main/image/98/C11>

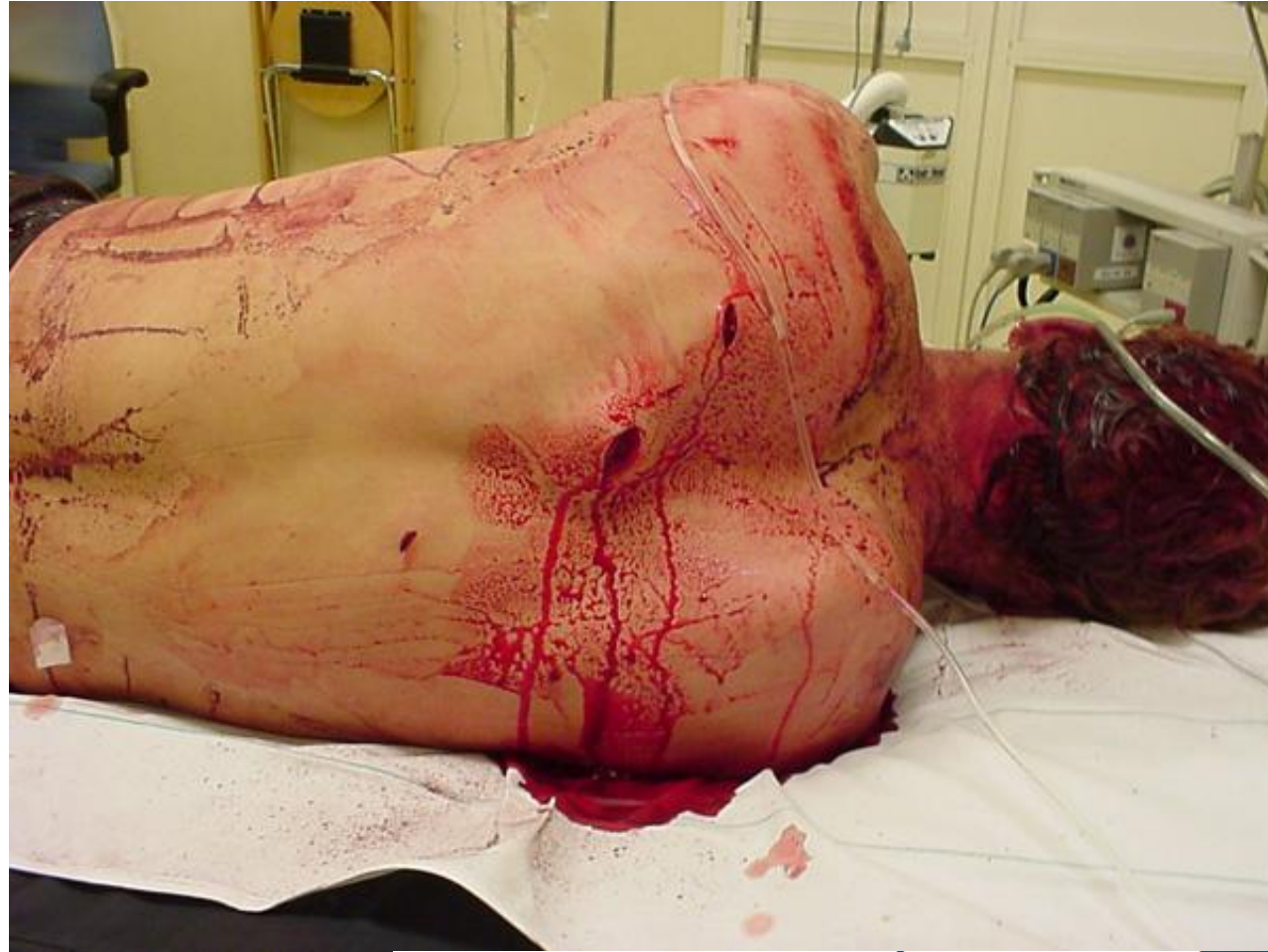The Athens Crossroad

8-10 November 2018

Zappeion Megaron Hall, Athens



# Exposure



Author unknown,

[http://www.trauma.org/images/image\\_library/chest0044b.jpg](http://www.trauma.org/images/image_library/chest0044b.jpg)



The Athens Crossroad

8-10 November 2018

Zappeion Megaron Hall, Athens



# Immediate Life Threatening Thoracic Injuries:

## Primary Survey

- Cardiac disruption/tamponade
- Tracheal disruption
- Open pneumothorax
- Tension pneumothorax
- Massive hemothorax (great vessels, pulmonary vessels)

The Athens Crossroad

8-10 November 2018

Zappeion Megaron Hall, Athens



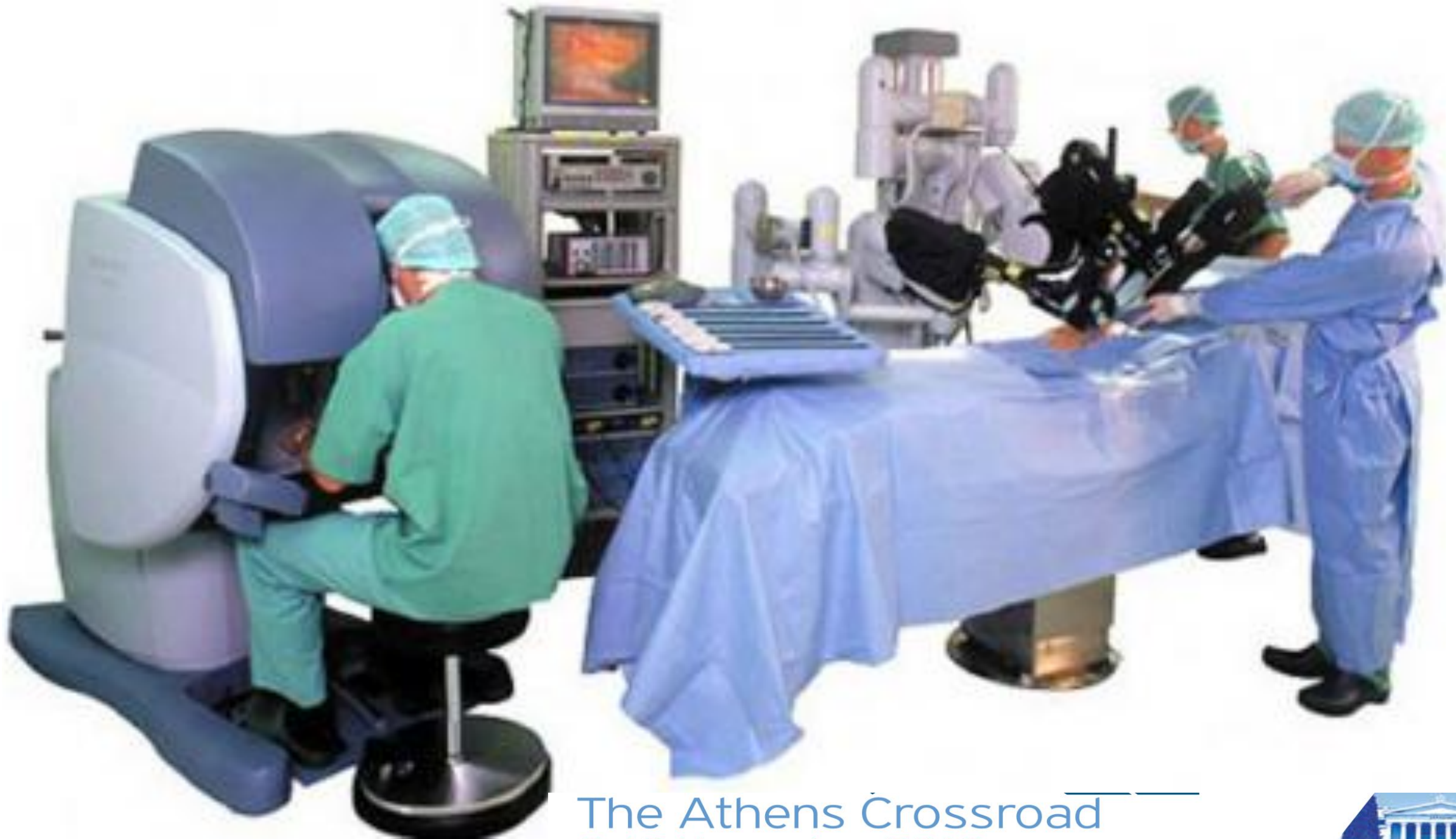

The Athens Crossroad

8-10 November 2018

Zappeion Megaron Hall, Athens





The Athens Crossroad

8-10 November 2018

Zappeion Megaron Hall, Athens



## • 6.3 Operative Preparation and Choice of Incision

- For patients in whom injury can be confidently isolated to one hemithorax and who are stable enough to allow for positioning, a **posterolateral thoracotomy** through the fifth intercostal space with the patient in the lateral decubitus position provides the best exposure for surgical treatment of pulmonary injuries as it allows all surfaces of the lung to be exposed and allows anterior and posterior exposure of the pulmonary hilum. However, victims of both blunt and penetrating lung trauma are at high risk for extrathoracic injuries that may require simultaneous management, and these considerations will necessarily influence the approach to the thoracic injury. For example, a patient requiring a simultaneous laparotomy will need to be placed supine, making a lateral or posterolateral thoracotomy impossible. Many pulmonary injuries can be definitively managed or at least damage controlled through an **anterolateral thoracotomy**. Occasionally these patients may need to be repositioned after extrathoracic injuries have been addressed to allow definitive repair of their thoracic injuries.

S. Di Saverio · G. Tugnoli · F. Catena  
L. Ansaloni · N. Naidoo *Editors*

**Trauma Surgery**

Volume 2

Thoracic and  
Abdominal Trauma

*Forewords by*  
Kenneth Mattox and Franco Baldoni



 Springer

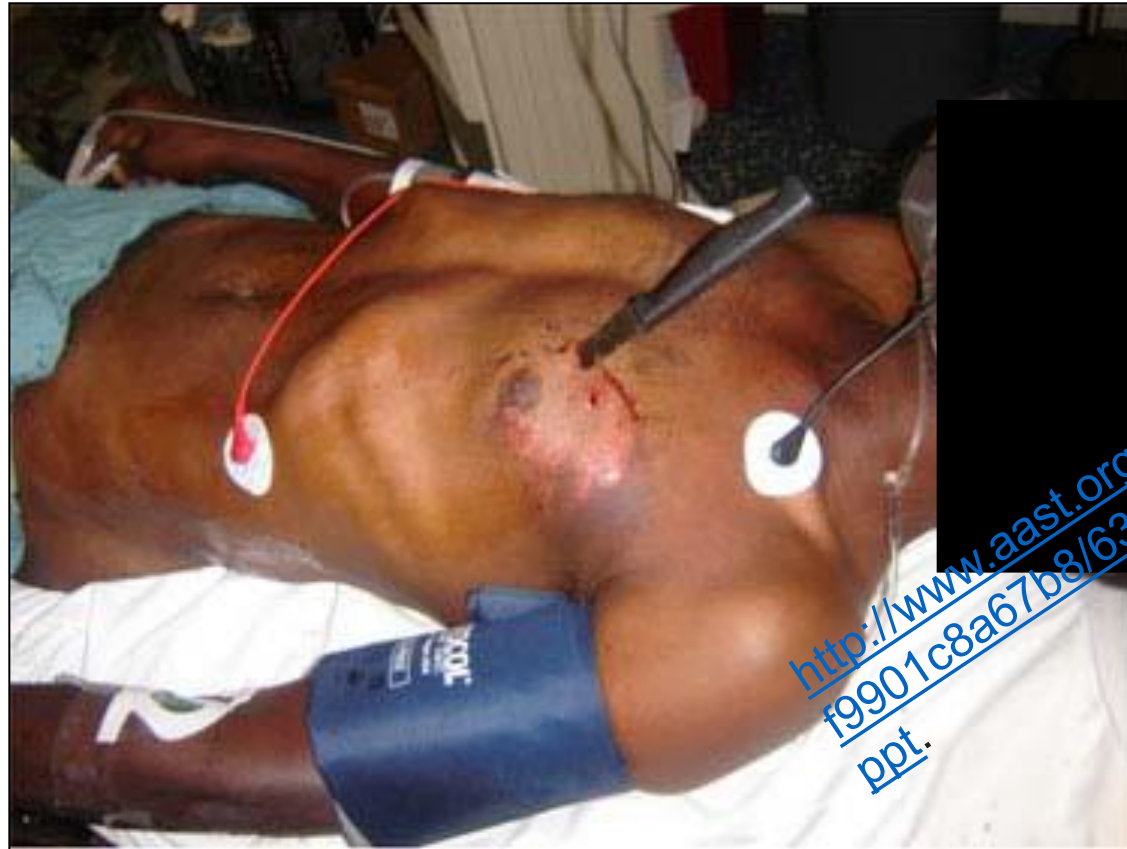The Athens Crossroad

8-10 November 2018

Zappeion Megaron Hall, Athens



*Immediate Life Threatening Thoracic Injuries:*  
***Cardiac Trauma***



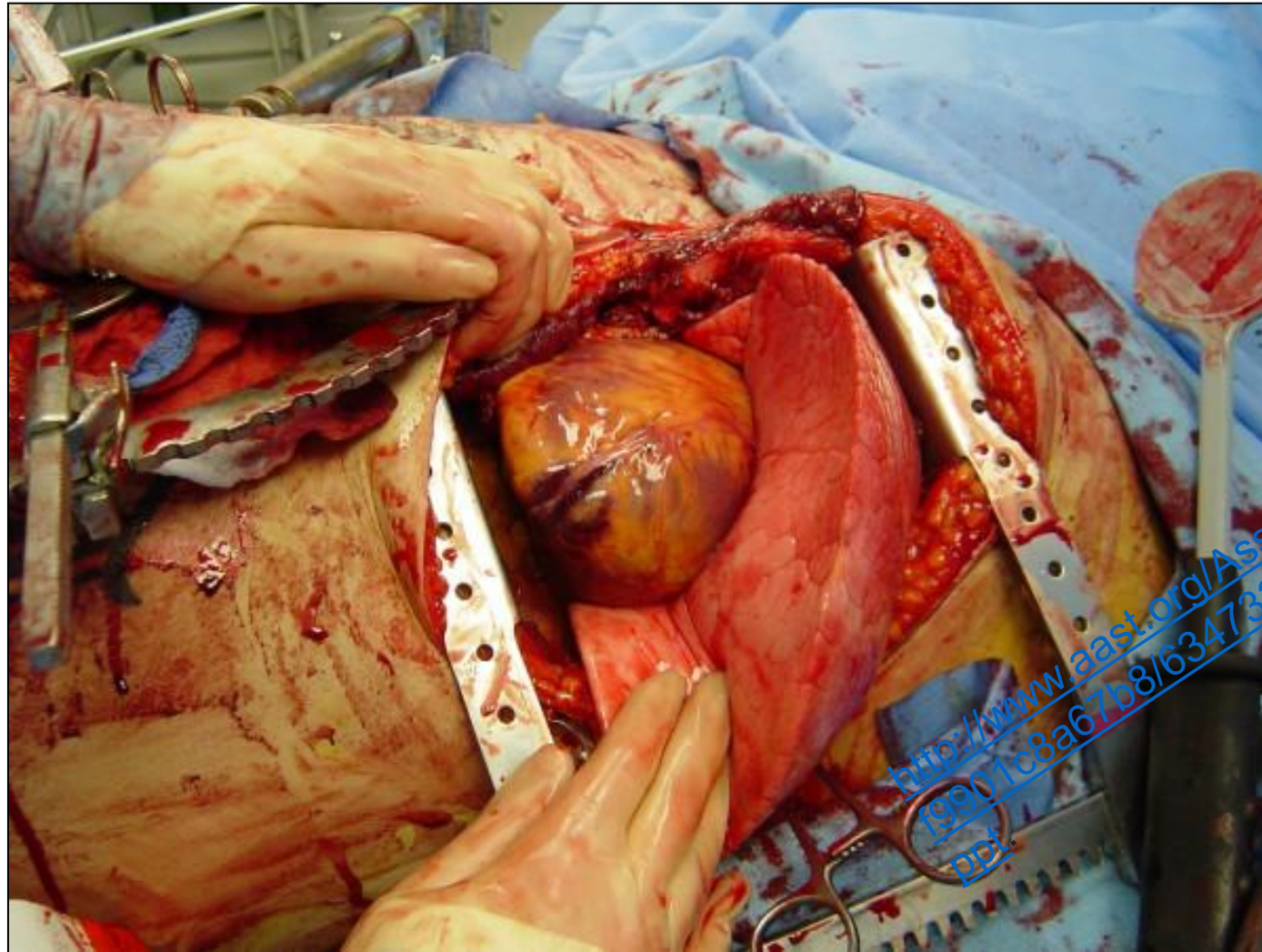
The Athens Crossroad

8-10 November 2018

Zappeion Megaron Hall, Athens



# ED Thoracotomy (EDT)



<http://www.aast.org/Assets/df512898-ced7-45c5-b729-19901c8a67b8/634733685283500000/rtc-thoracic-trauma-pp1>

The Athens Crossroad

8-10 November 2018

Zappeion Megaron Hall, Athens



# Rationale for EDT

- Resuscitate agonal patient with penetrating cardiothoracic injuries
- Evacuation of pericardial tamponade
- Control intra-thoracic hemorrhage
- Perform open CPR
- Repair cardiac injuries
- Apply x-clamp to thoracic aorta
- Apply hilar x-clamp to lung
- Aspirate air embolism

Asensio JA, et.al. *An evidence-based critical appraisal of emergency department thoracotomy*, Evidence-Based Surgery 2003; 1(1) 11-21.

The Athens Crossroad

8-10 November 2018

Zappeion Megaron Hall, Athens



# Indications for ED Thoracotomy

## Indications:

1. Salvageable post-injury cardiac arrest:
  - ✓ Patients sustaining witnessed penetrating trauma with < 15 minutes of pre-hospital CPR
  - ✓ Patients sustaining witnessed blunt trauma with < 5 minutes of pre-hospital CPR
2. Persistent severe post-injury hypotension (SBP<60mmHg) due to:
  - ✓ Cardiac tamponade
  - ✓ Hemorrhage – intra-thoracic, intra-abdominal, extremity, cervical
  - ✓ Air embolism



# *Contra-indications for ED Thoracotomy*

## Contraindications:

1. Penetrating trauma: CPR >15 minutes and no signs of life (pupillary response, respiratory effort, motor activity:
2. Blunt trauma: CPR > minutes and no signs of life or asystole

C Clay Cothren and Ernest E Moore *Emergency department thoracotomy for the critically injured patient: Objectives, indications, and outcomes* Department of Surgery, Denver Health Medical Center and the University of Colorado Health Sciences Center, Denver, CO, USA *World Journal of Emergency Surgery* 2006, 1:4

The Athens Crossroad  
8-10 November 2018  
Zappeion Megaron Hall, Athens



# Emergency Department Thoracotomy: Outcomes

Review of 42 published series

Survivors/ Total EDT	Survivors/ Penetrating Trauma	Survivors/ Blunt Trauma
537/8744 (6.1%)	500/8619 (5.8%)	35/7945 (0.44%)

Asensio JA, et.al. *An evidence-based critical appraisal of emergency department thoracotomy*, Evidence-Based Surgery 2003; 1(1) 11-21.

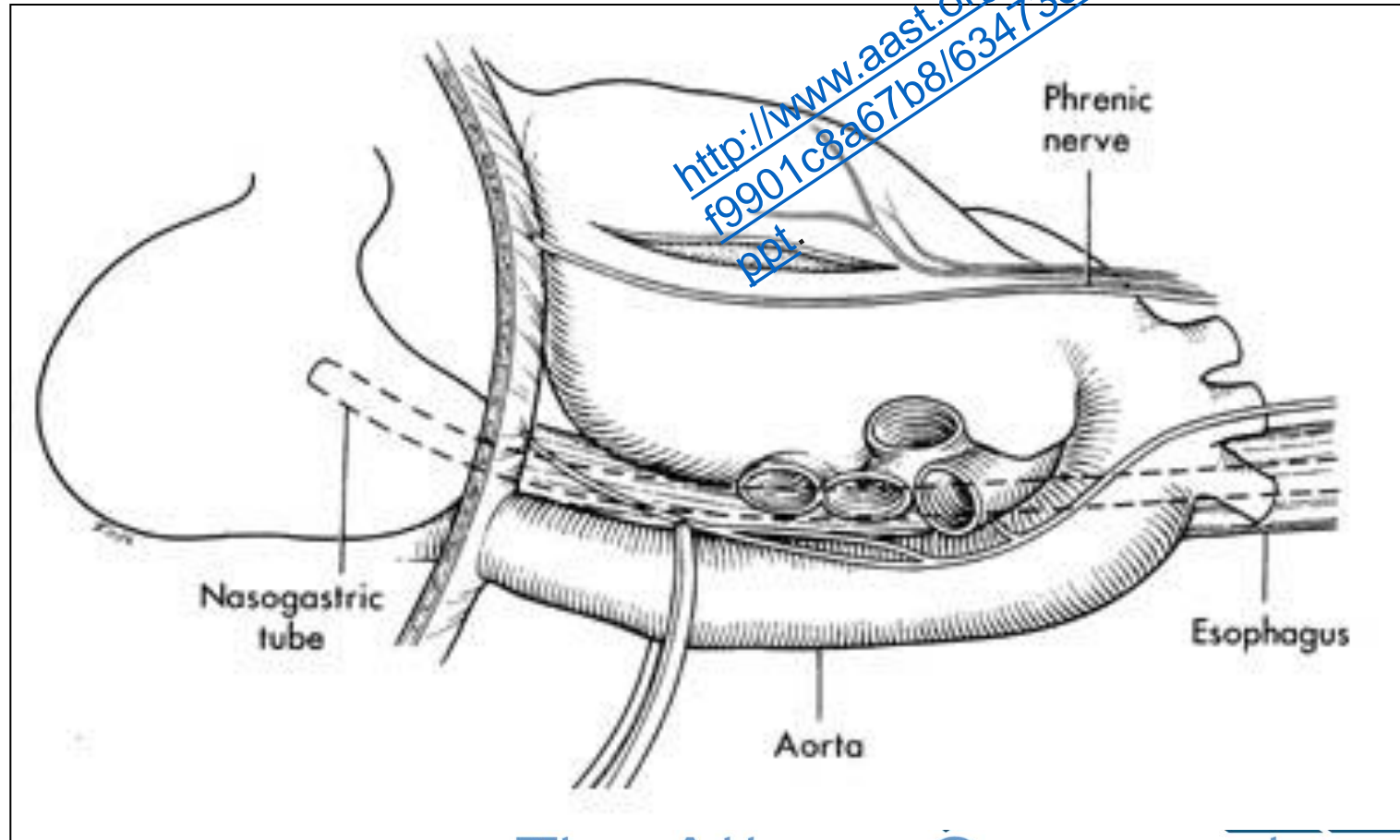
The Athens Crossroad

8-10 November 2018

Zappeion Megaron Hall, Athens



# Application of Aortic Cross Clamp

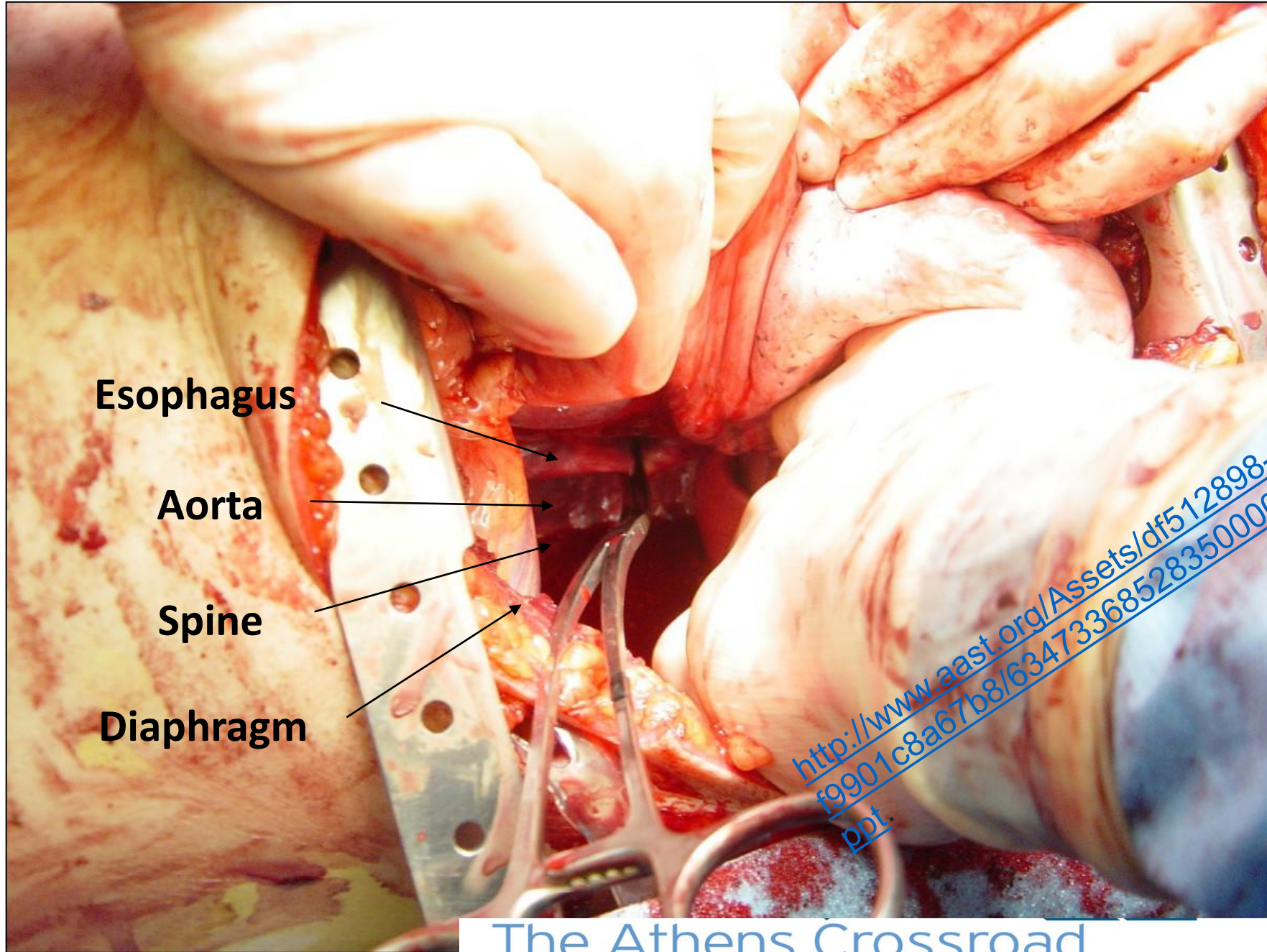


The Athens Crossroad

8-10 November 2018

Zappeion Megaron Hall, Athens





**Esophagus**

**Aorta**

**Spine**

**Diaphragm**

<http://www.aast.org/Assets/df512898-ced7-45c5-b729-f9901c8a67b8/634733685283500000/rtc-thoracic-trauma-ppt>

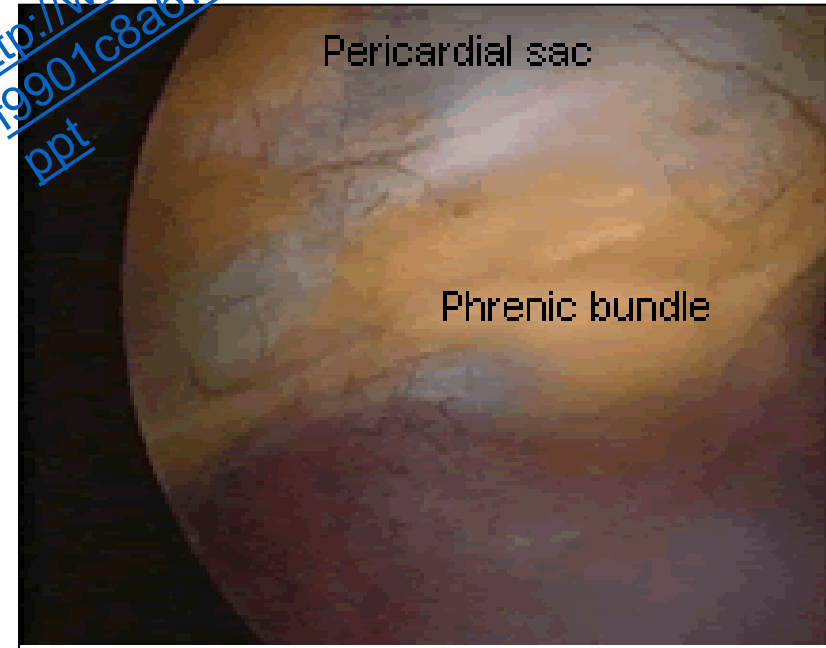
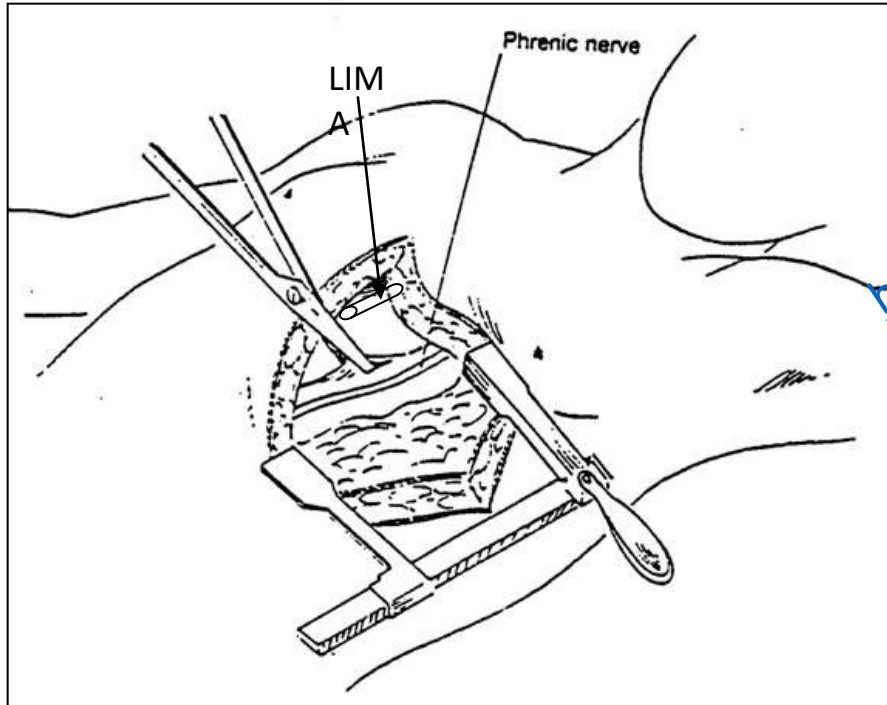
**The Athens Crossroad**

**8-10 November 2018**

Zappeion Megaron Hall, Athens



# Vertical Pericardial Incision



<http://www.aast.org/Assets/df512898-ced7-45c5-b729-f9901c8a67b8/634733685283500000/rtc-thoracic-trauma.ppt>

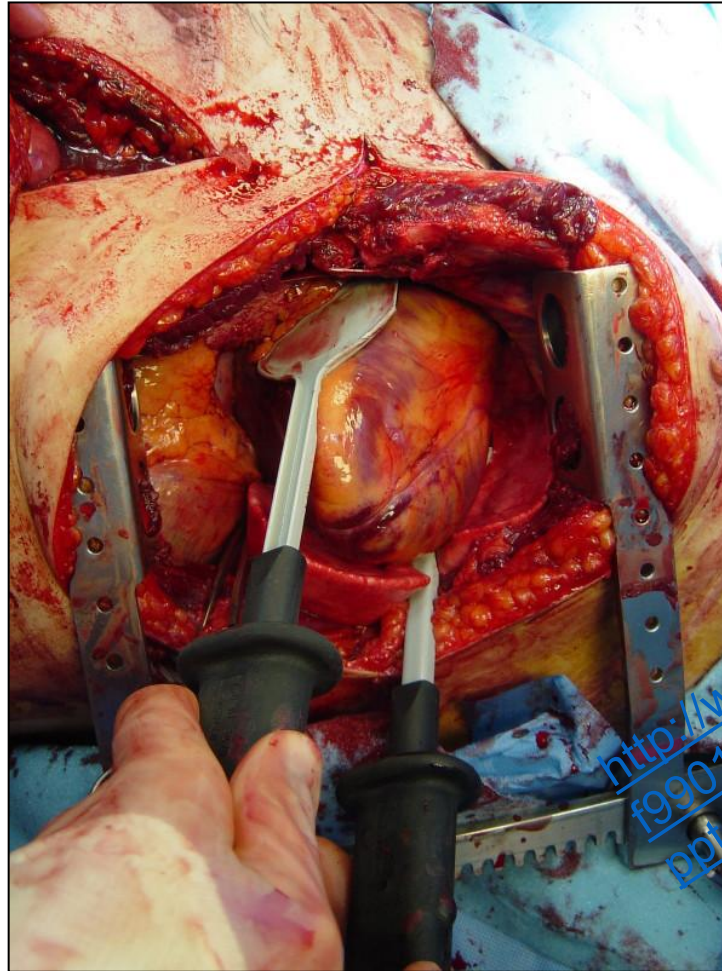
The Athens Crossroad

8-10 November 2018

Zappeion Megaron Hall, Athens



# Internal Paddles for Direct Cardioversion



<http://www.aast.org/Assets/df512898-ced7-45c5-b729-f9901c8a67b8/634733685283500000/rtc-thoracic-trauma-ppt>

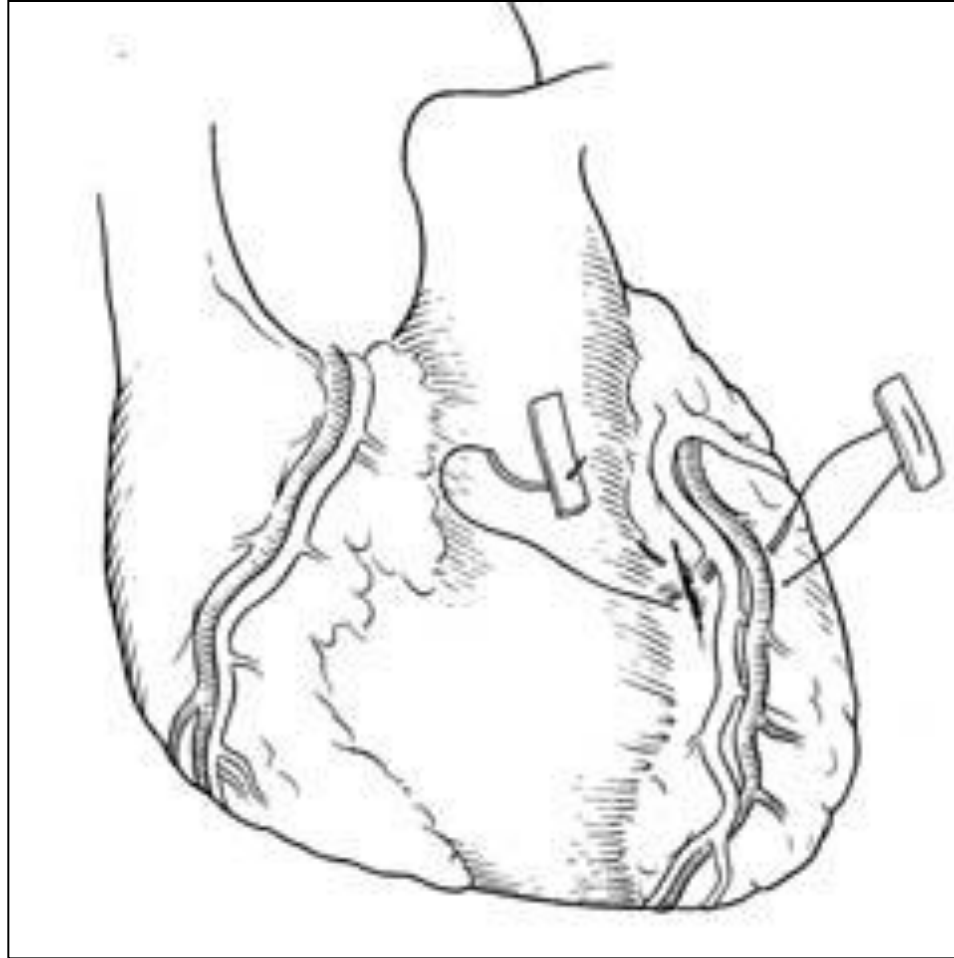
The Athens Crossroad

8-10 November 2018

Zappeion Megaron Hall, Athens



# Laceration Adjacent to Coronary Artery



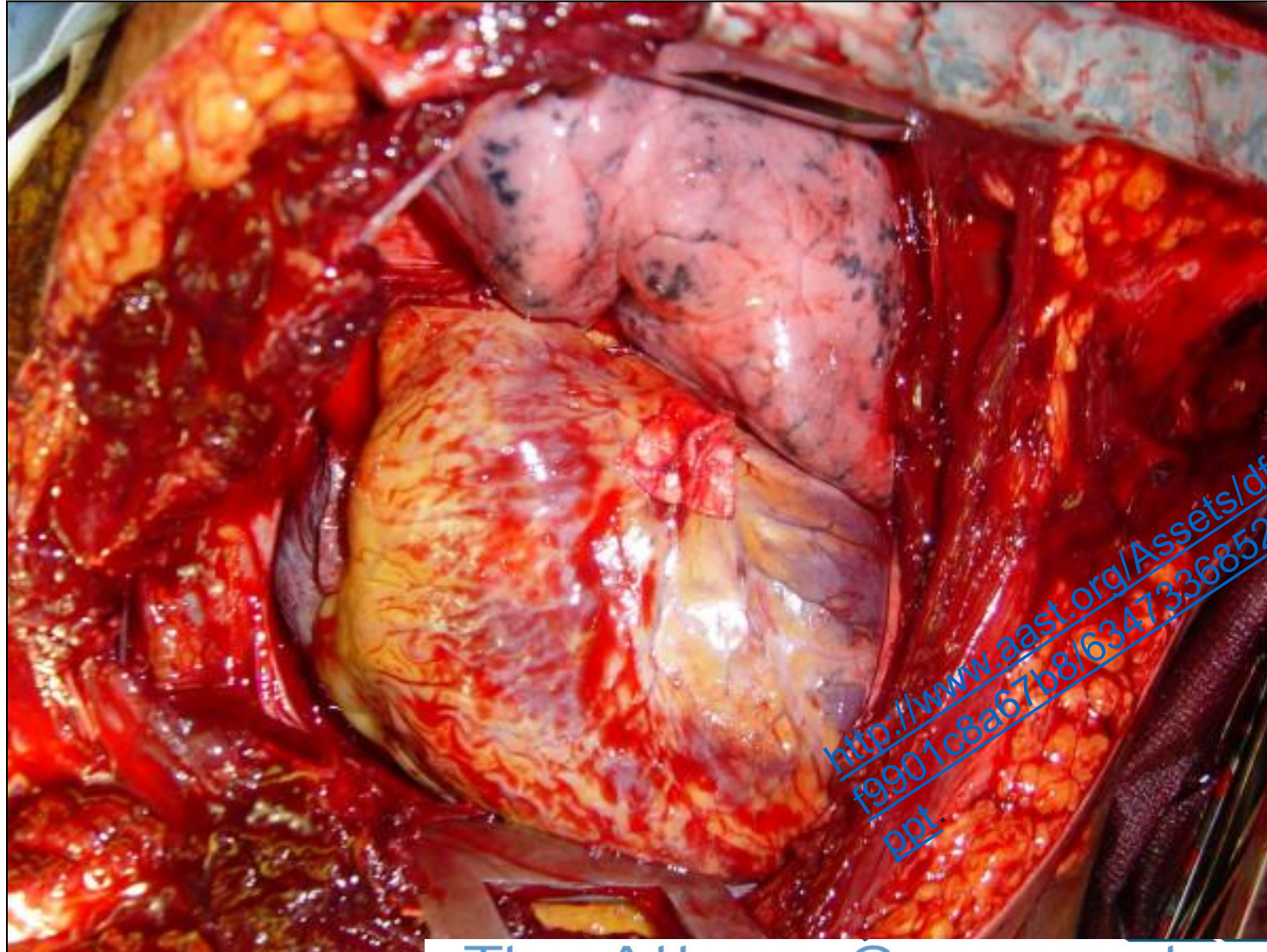
The Athens Crossroad

8-10 November 2018

Zappeion Megaron Hall, Athens



# Laceration Adjacent to Coronary Artery



<http://www.east.org/Assets/df512898-ced7-45c5-b729-f9901c8a67b8/634733685283500000/rtc-thoracic-trauma-ppt>

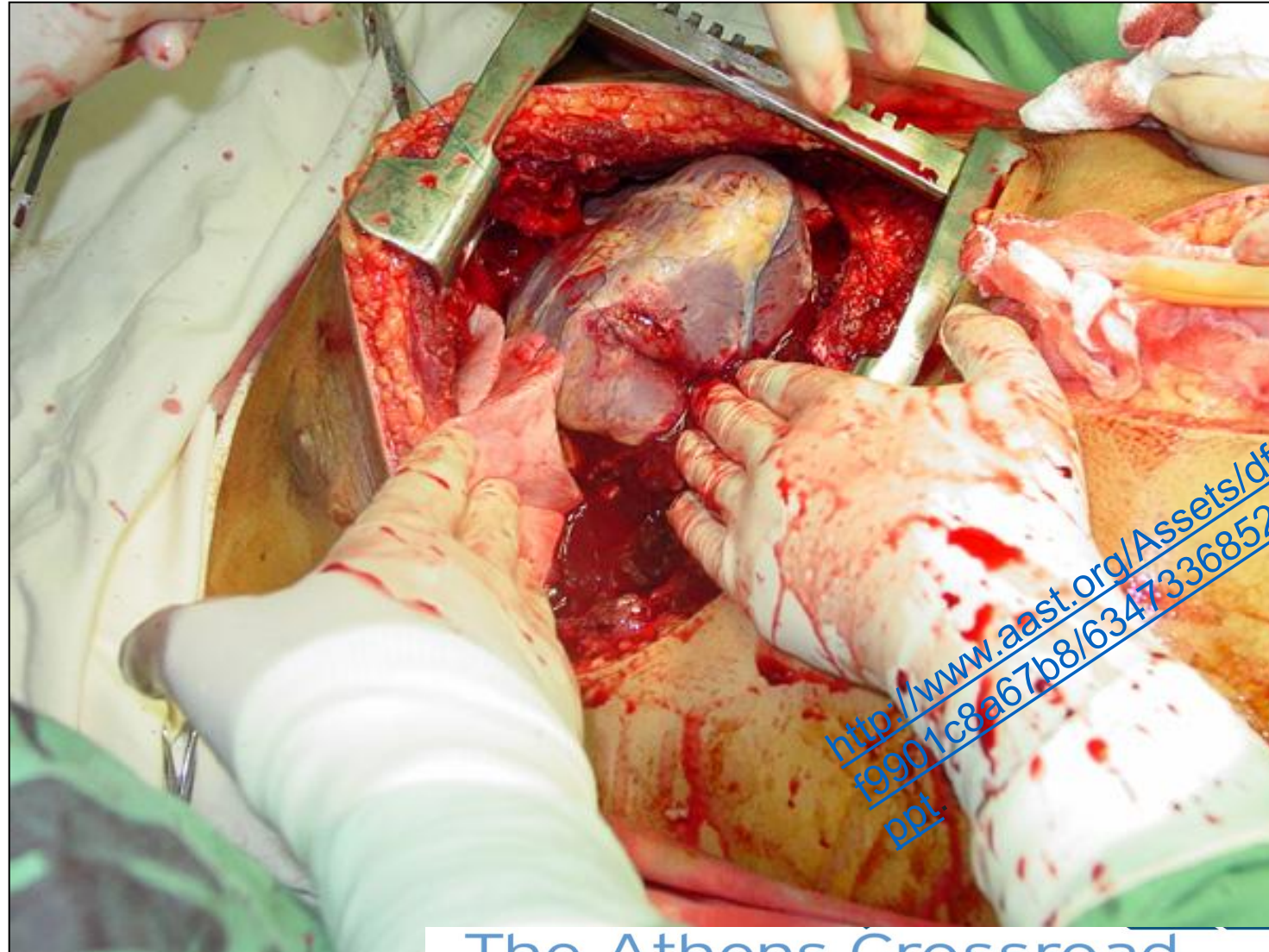
The Athens Crossroad

8-10 November 2018

Zappeion Megaron Hall, Athens



# Ventricular Lacerations and Repairs



<http://www.aast.org/Assets/df512898-ced7-45c5-b729-f9901c8a67b8/634733685283500000/rtc-thoracic-trauma-ppt>

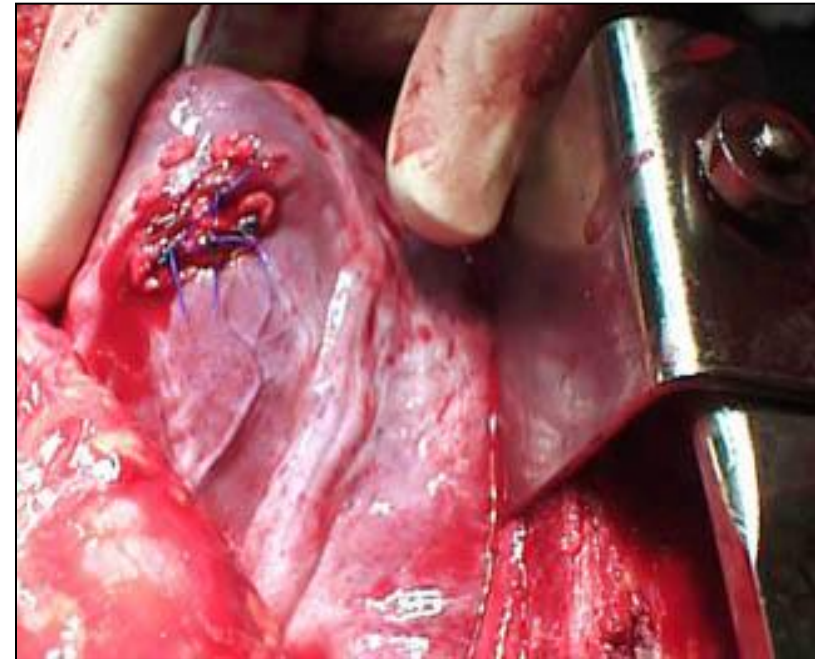
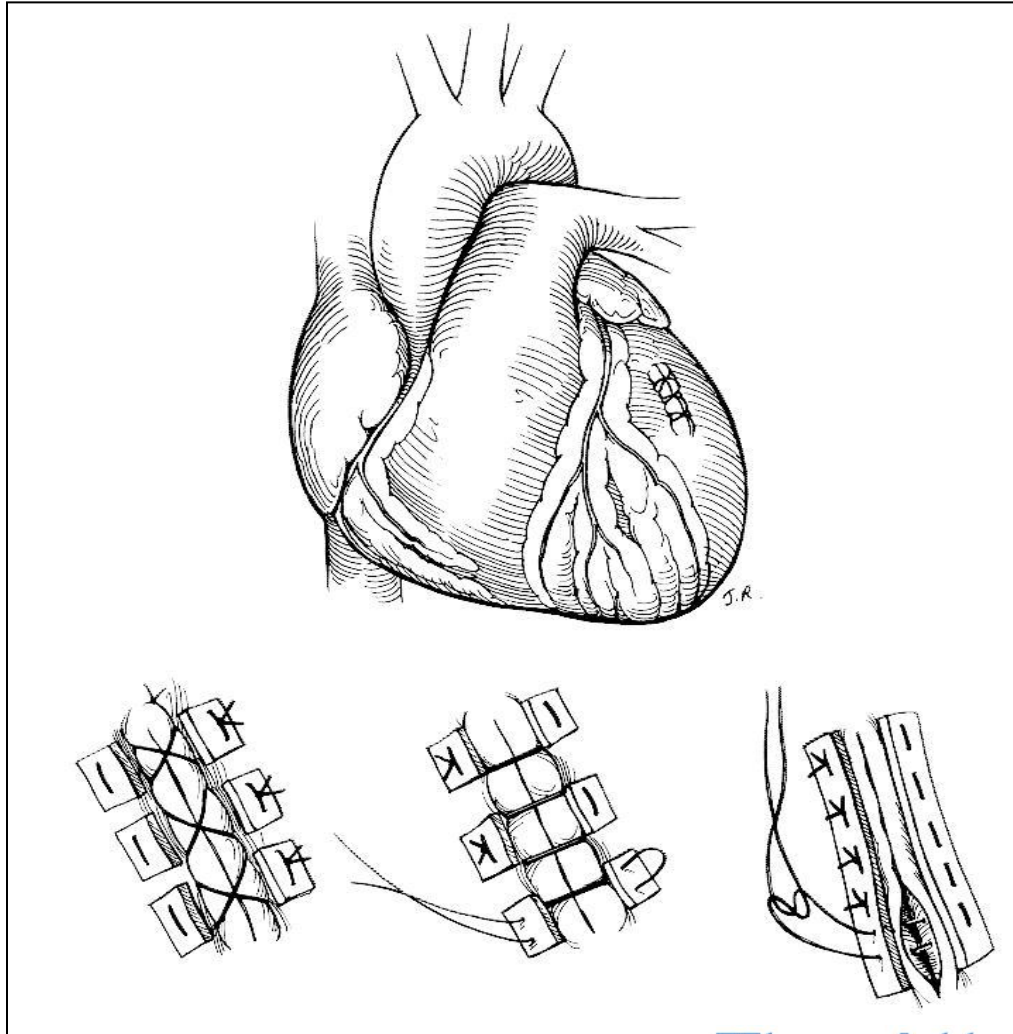
The Athens Crossroad

8-10 November 2018

Zappeion Megaron Hall, Athens



# Ventricular Lacerations and Repairs



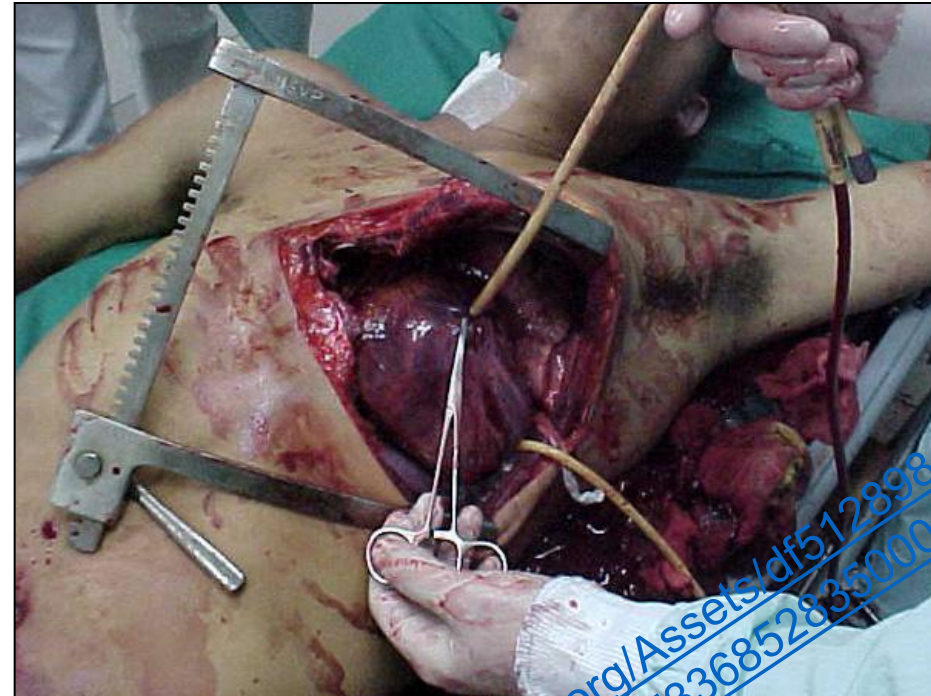
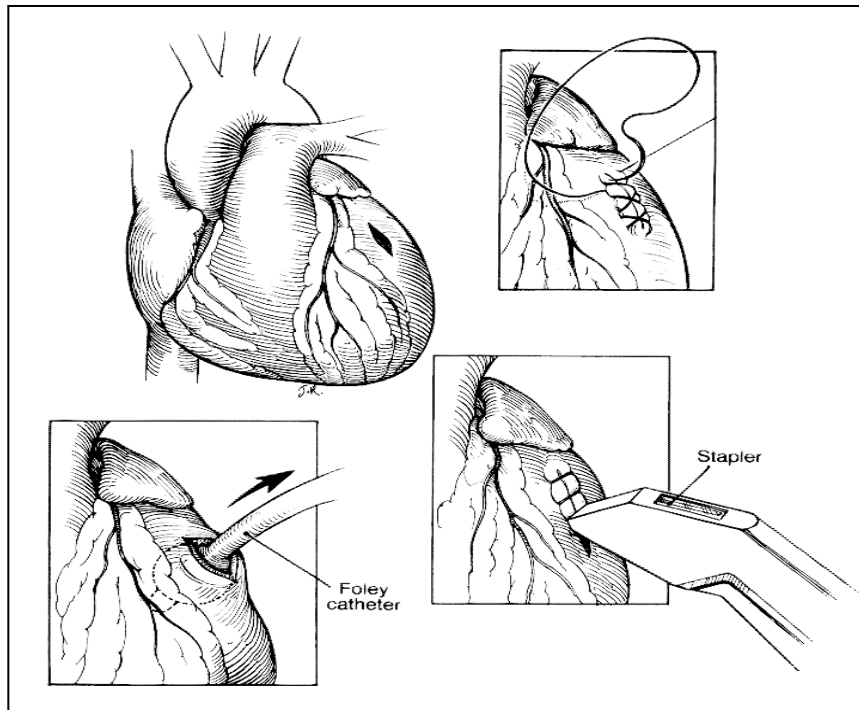
The Athens Crossroad

8-10 November 2018

Zappeion Megaron Hall, Athens



# Ventricular Lacerations and Repairs



<http://www.aast.org/Assets/df512898-ced7-45c5-b729-2901c8a67b8/6347336852835000000/rtc-thoracic-traum>

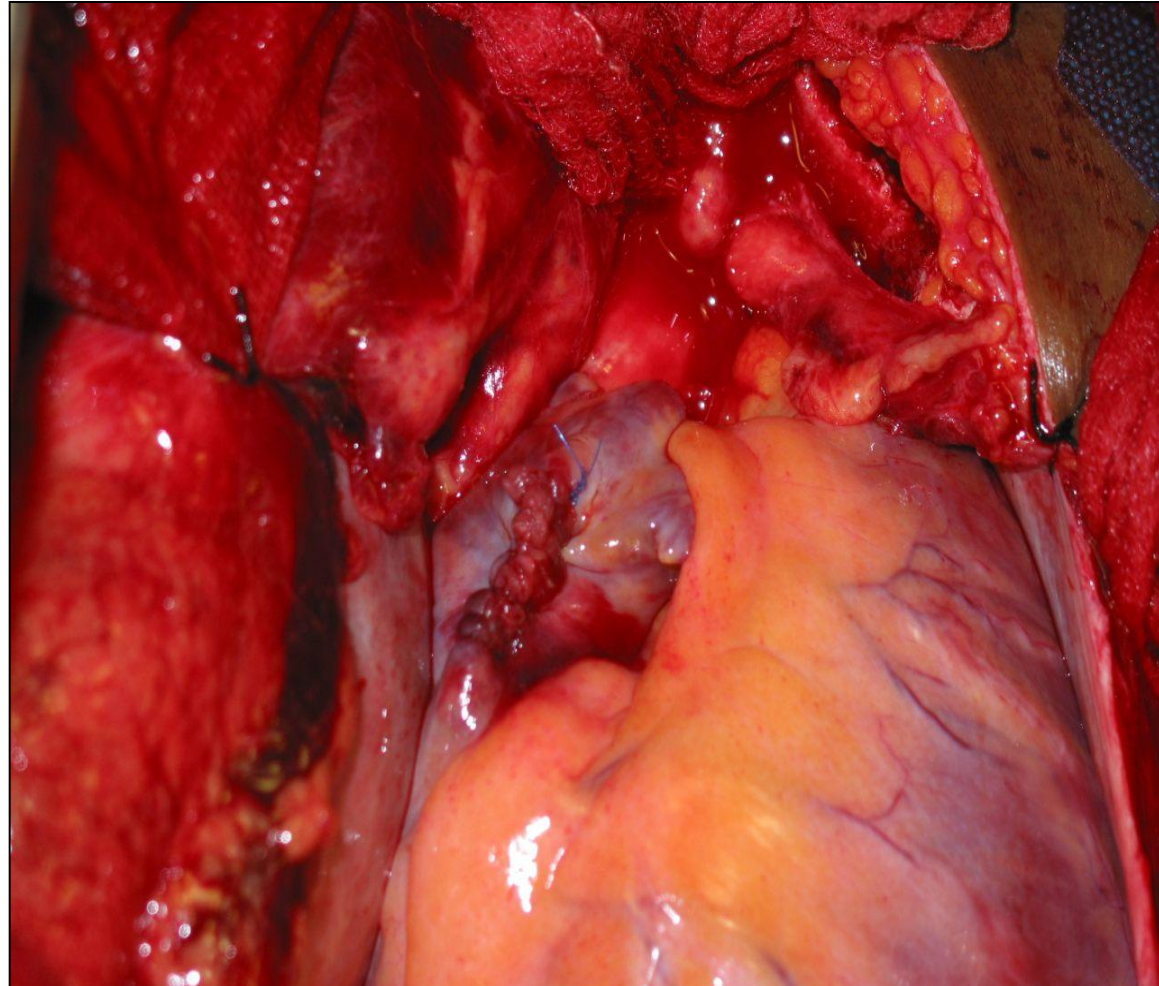
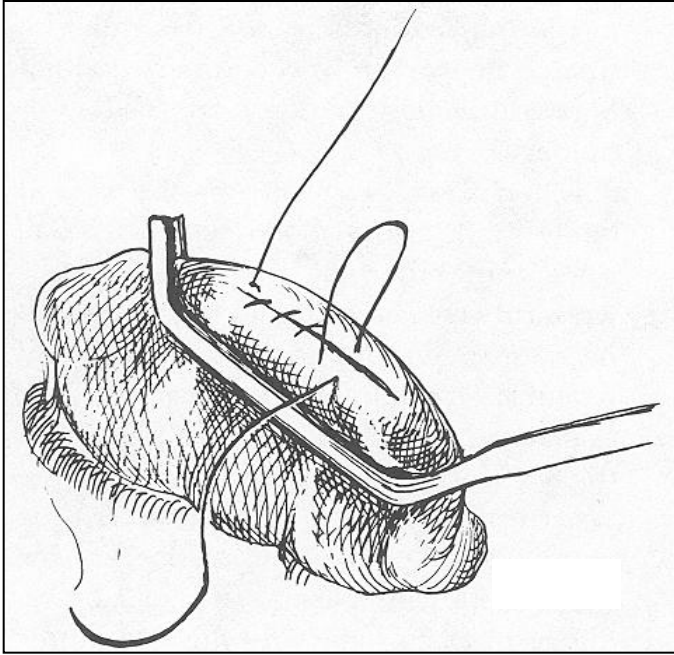
The Athens Crossroad

8-10 November 2018

Zappeion Megaron Hall, Athens



# Atrial Lacerations and Repairs



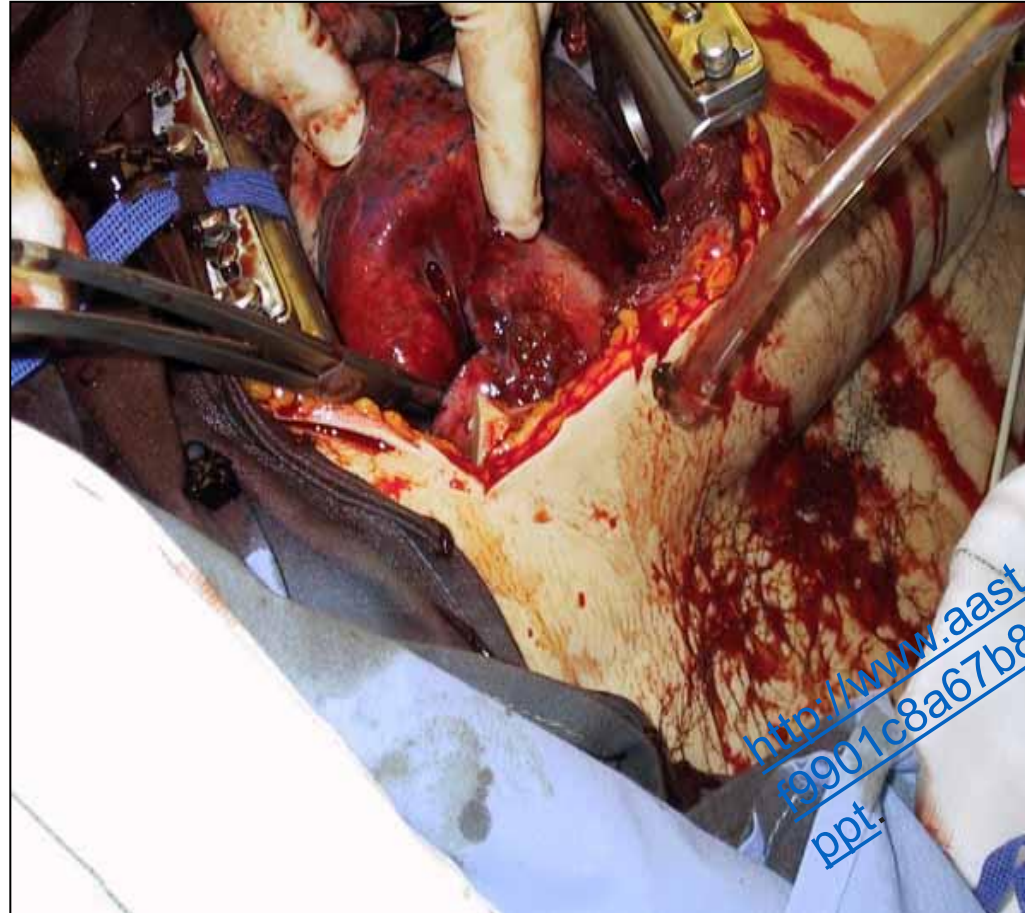
The Athens Crossroad

8-10 November 2018

Zappeion Megaron Hall, Athens



# Application of Pulmonary Hilar Cross Clamp



<http://www.aast.org/Assets/df512898-ced7-45c5-b729-f9901c8a67b8/634733685283500000/rtc-thoracic-trauma-ppt>

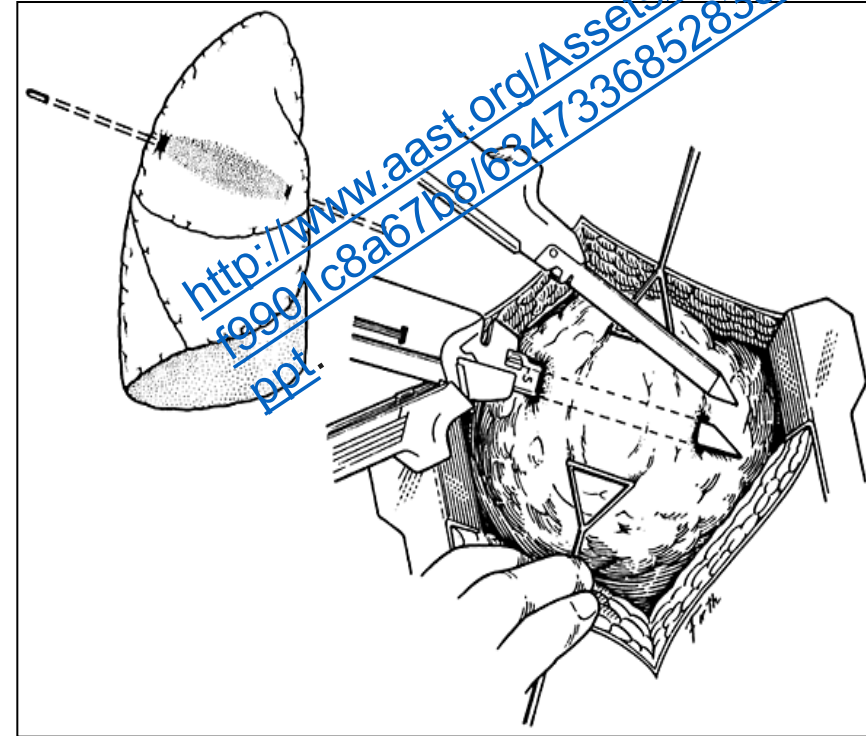
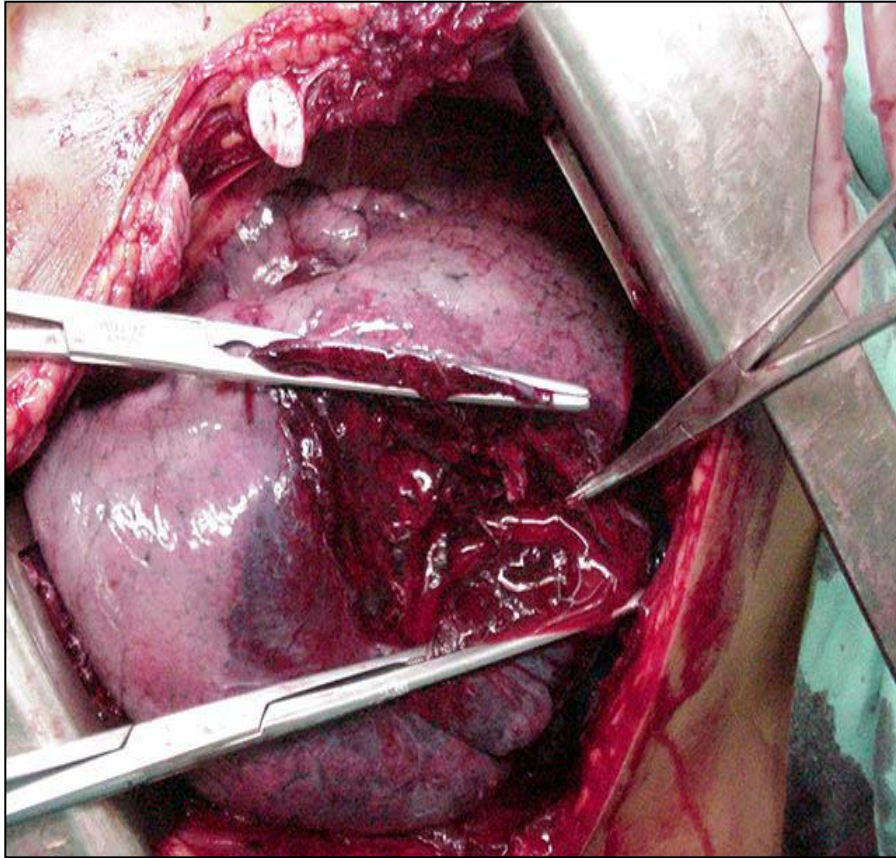
The Athens Crossroad

8-10 November 2018

Zappeion Megaron Hall, Athens



# Pulmonary Tractotomy



## Lung-Sparing Surgery After Penetrating Trauma Using Tractotomy, Partial Lobectomy, and Pneumonorrhaphy

George C. Velmahos, MD, PhD; Craig Baker, MD; Demetrios Demetriades, MD, PhD;  
Jeremy Goodman; James A. Murray, MD; Juan A. Asensio, MD

*Arch Surg.* 1999;134:186-189.

The Athens Crossroad

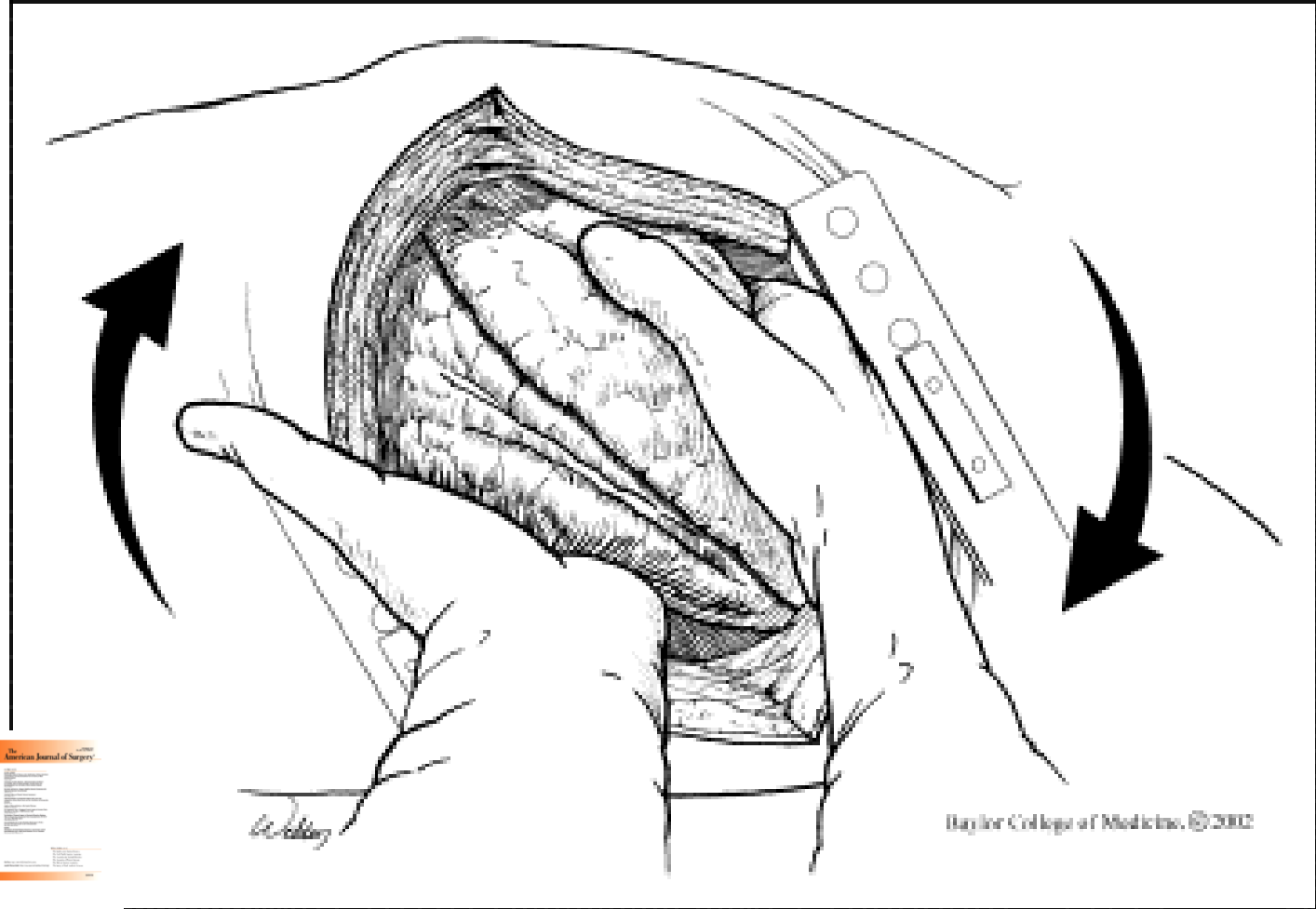
8-10 November 2018

Zappeion Megaron Hall, Athens



<http://www.aast.org/Assets/df512898-ced7-45c5-b729-19991c8a6708/634733685283500000/rtc-thoracic-trauma-ppt.>

# Pulmonary Twist



The American Journal of Surgery  
Volume 186, Issue 1, July 2003, Pages 49-52



How I do it

The pulmonary hilum twist as a thoracic damage control procedure

Alison Wilson M.D. <sup>a</sup>, Matthew J. Wall Jr. M.D. <sup>a</sup>, Robert Maxson M.D. <sup>a</sup>, Kenneth Mattox M.D. <sup>a</sup>

Show more

[https://doi.org/10.1016/S0002-9610\(03\)00102-8](https://doi.org/10.1016/S0002-9610(03)00102-8)

Get rights and content

## The Athens Crossroad

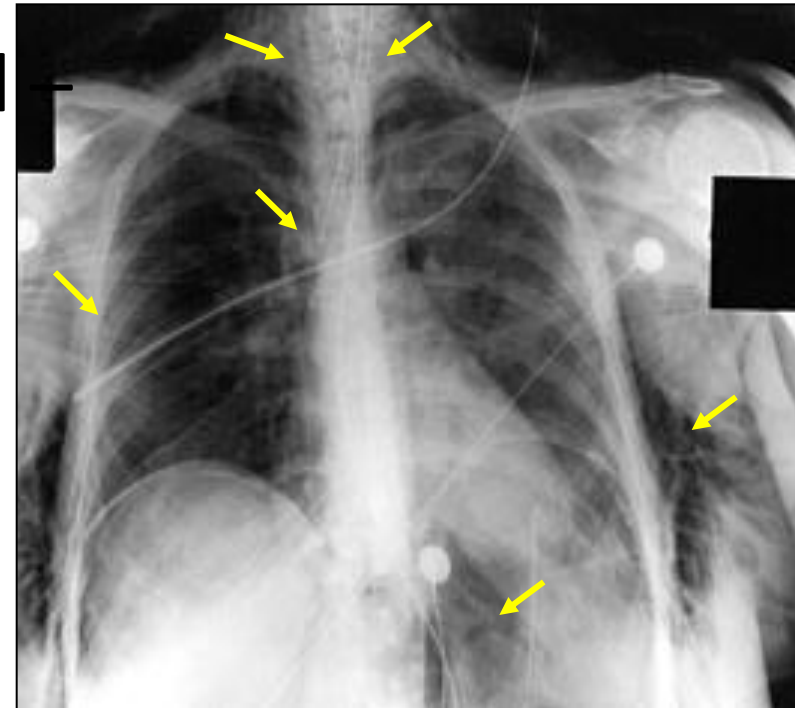
### 8-10 November 2018

Zappeion Megaron Hall, Athens



# *Immediate Life Threatening Thoracic Injuries: Tracheal Disruption*

- ✓ Massive subcutaneous emphysema in chest wall
- displaced trachea
- ✓ Cervical, facial subcutaneous emphysema
- ✓ Hemoptysis
- ✓ Blunt injuries almost always within 1" carina



The Athens Crossroad

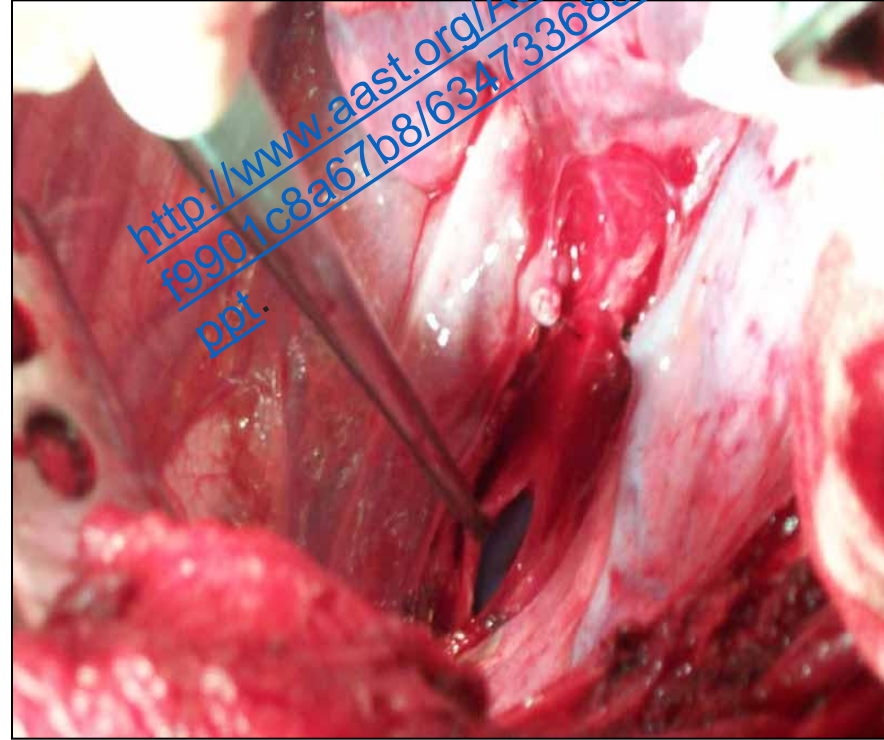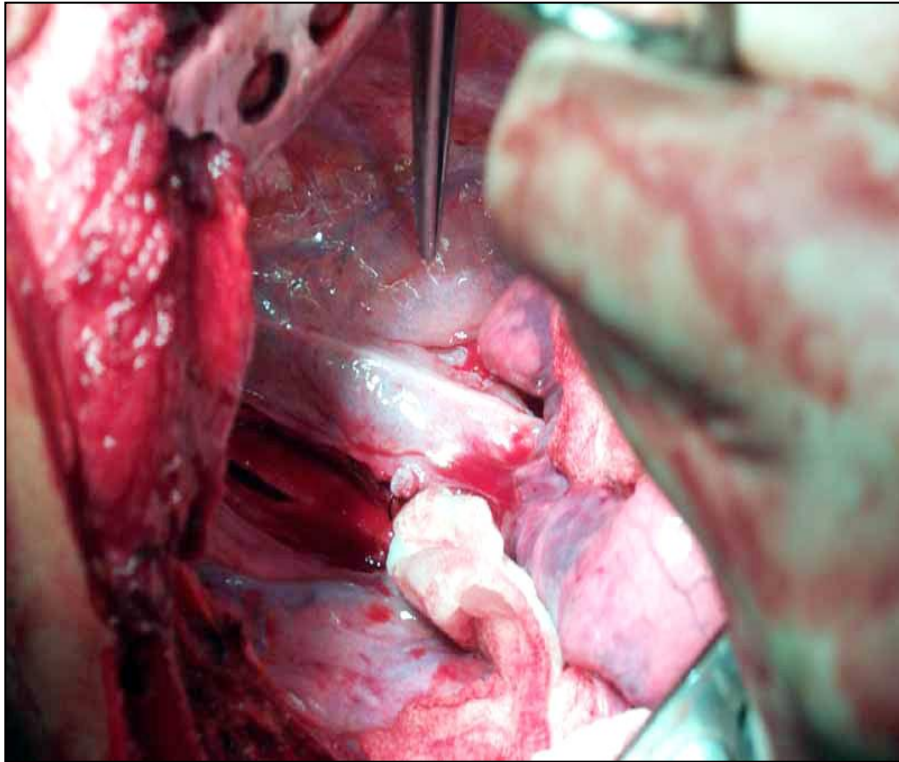
8-10 November 2018

Zappeion Megaron Hall, Athens



# *Immediate Life Threatening Thoracic Injuries: Tracheal Disruption*

<http://www.aast.org/Assets/df512898-ced7-45c5-b729-19901c8a67b8/634733685283500000/rtc-thoracic-trauma-ppt>



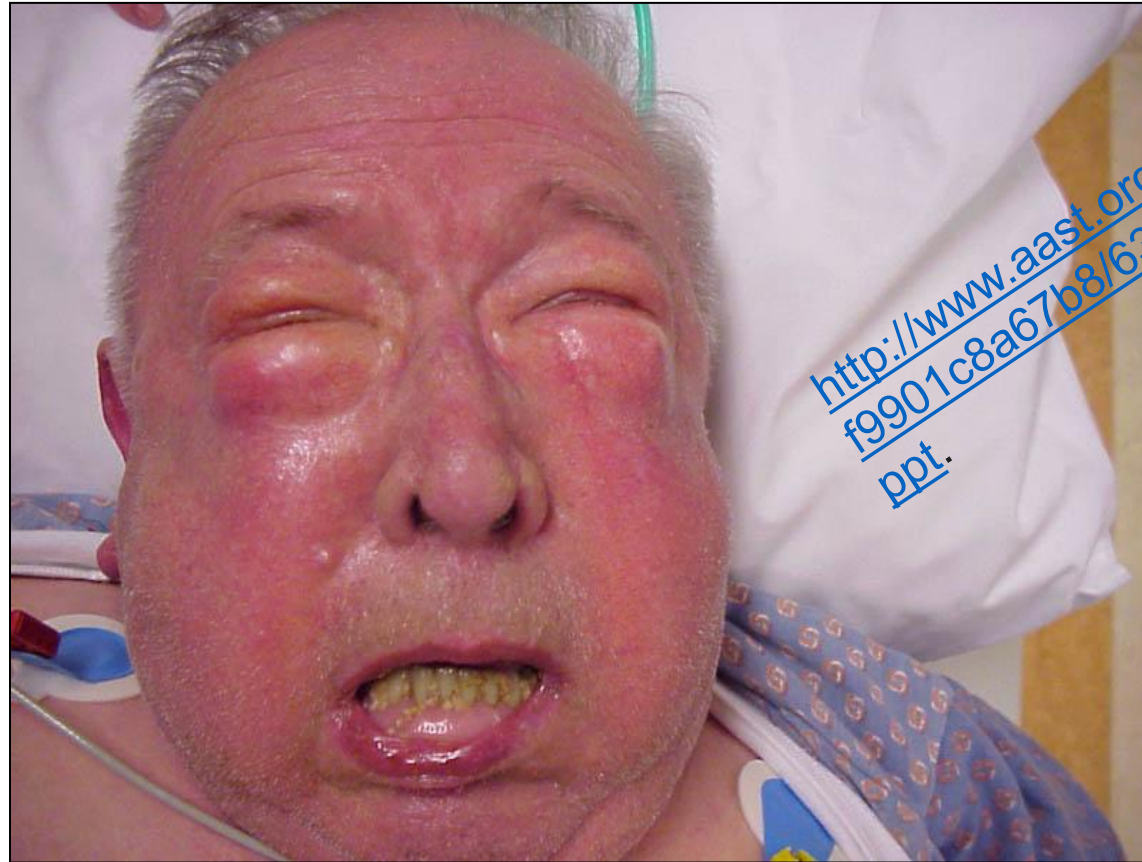The Athens Crossroad

8-10 November 2018

Zappeion Megaron Hall, Athens



*Immediate Life Threatening Thoracic Injuries:*  
***Tracheal Disruption***



<http://www.aast.org/Assets/df512898-ced7-45c5-b729-f9901c8a67b8/634733685283500000/rtc-thoracic-trauma.ppt>

The Athens Crossroad

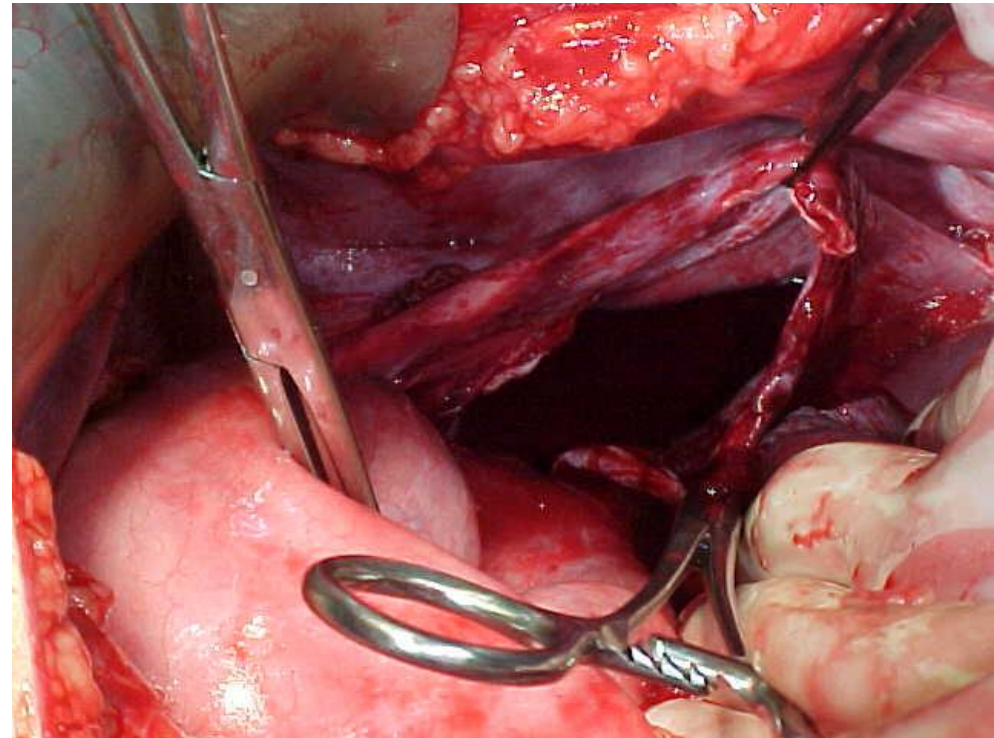
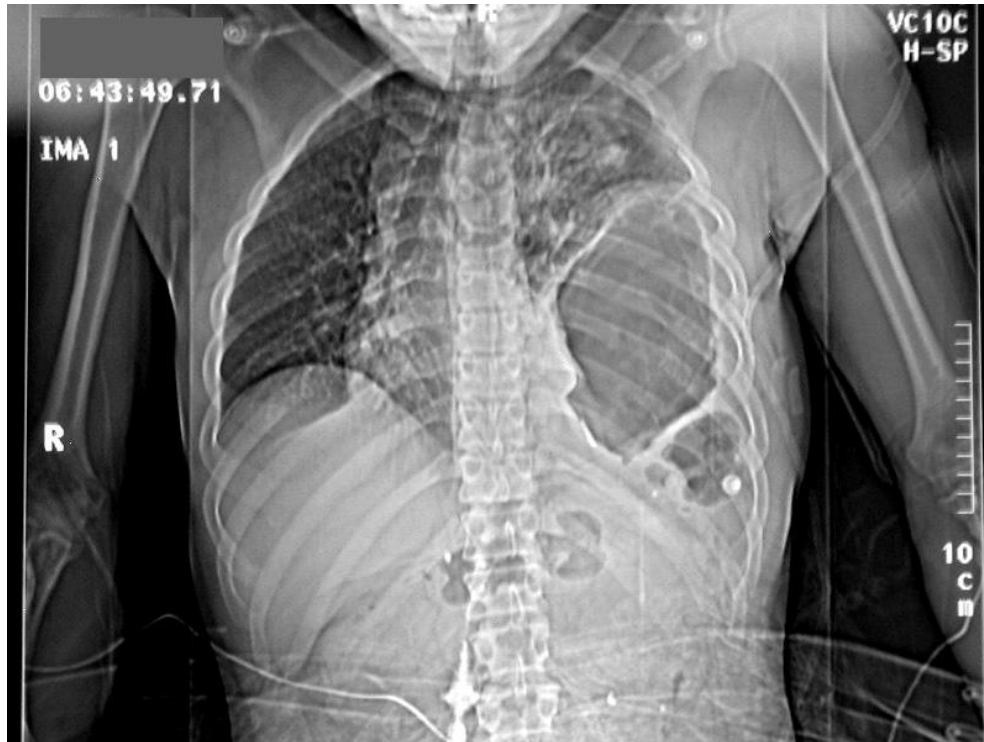8-10 November 2018

Zappeion Megaron Hall, Athens



# DIAPHRAGM RUPTURE

- Associated with blunt trauma or blast injury
- Can be due to stab wounds



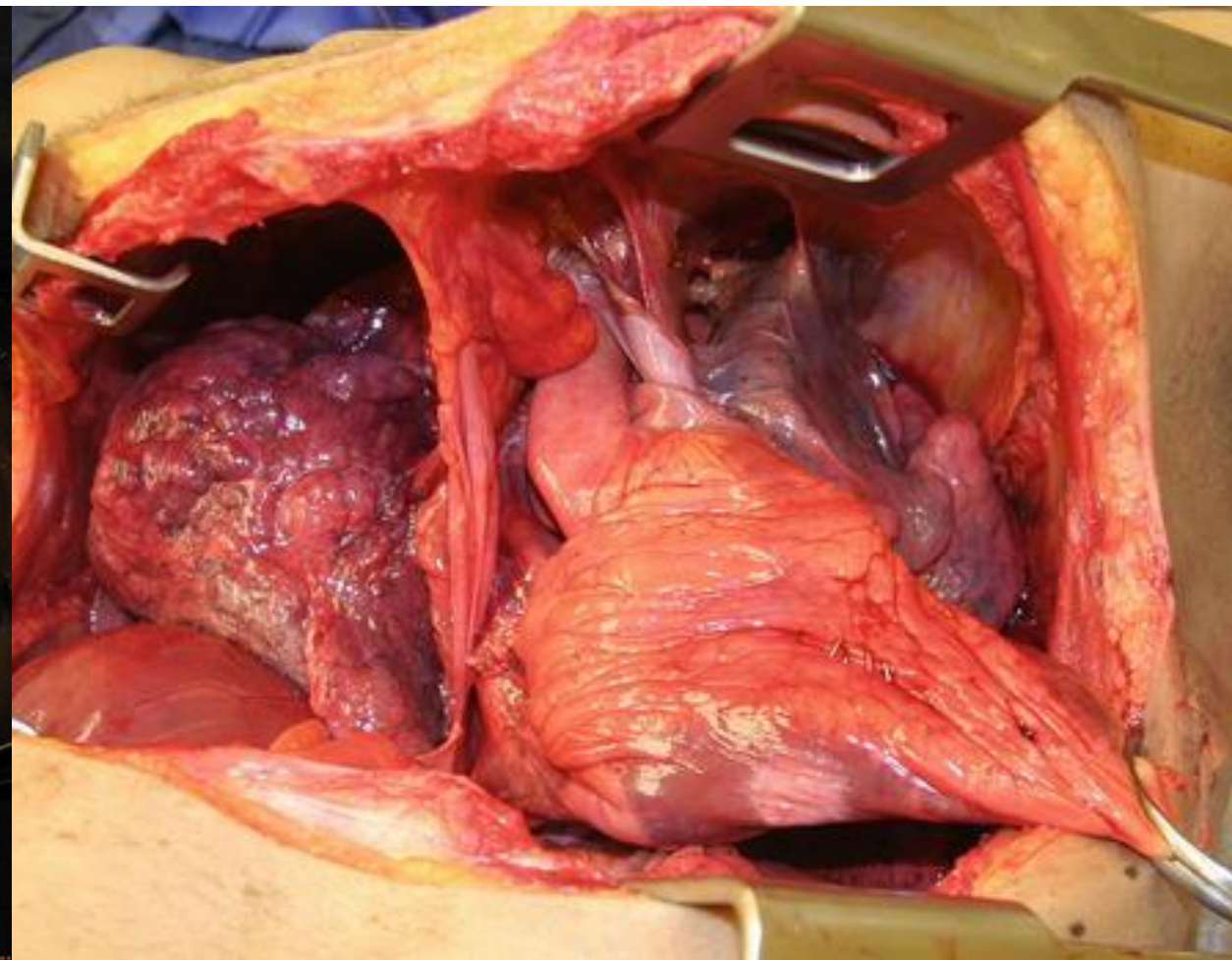
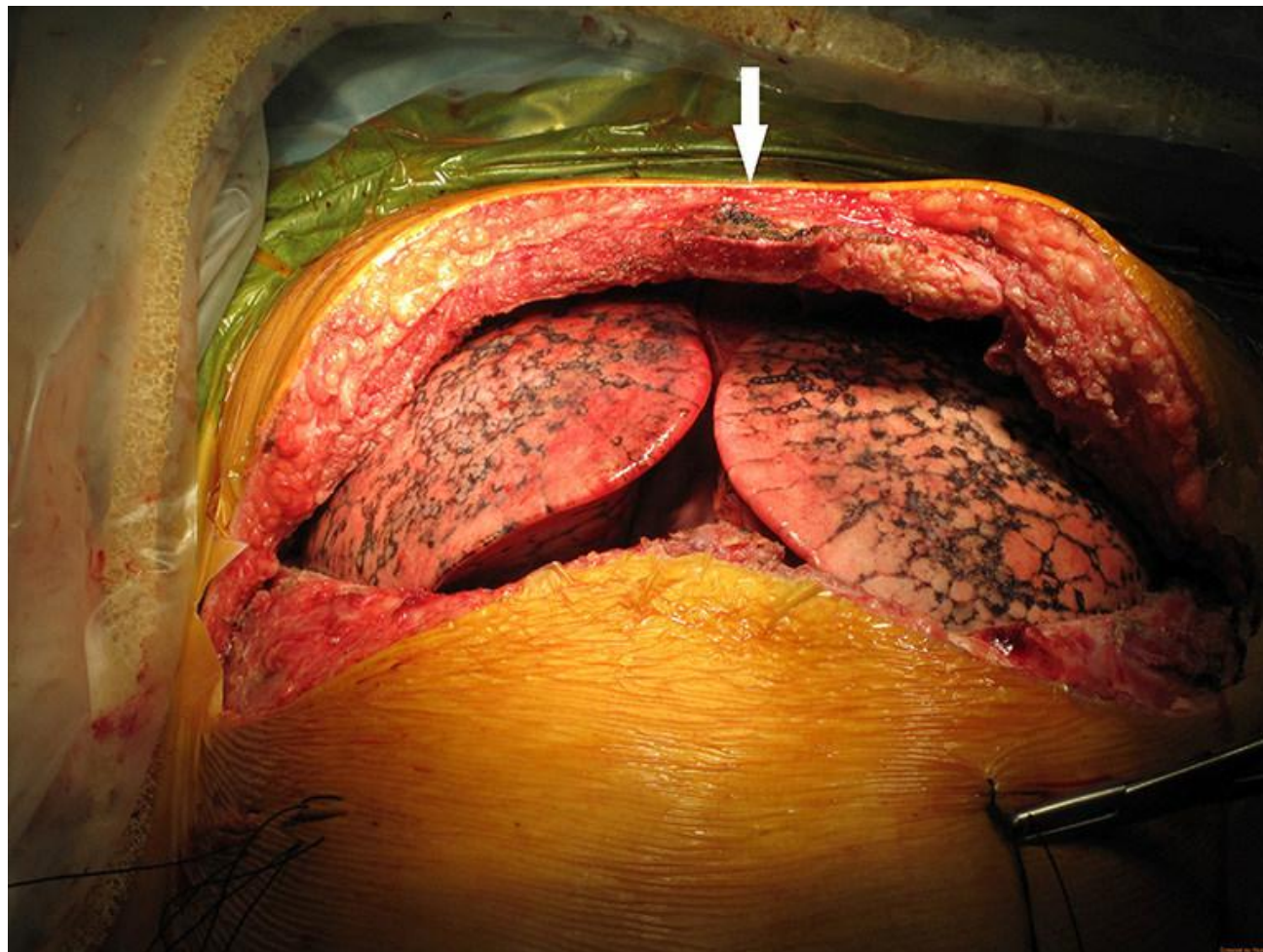
The Athens Crossroad

8-10 November 2018

Zappeion Megaron Hall, Athens



# Clamshell incision

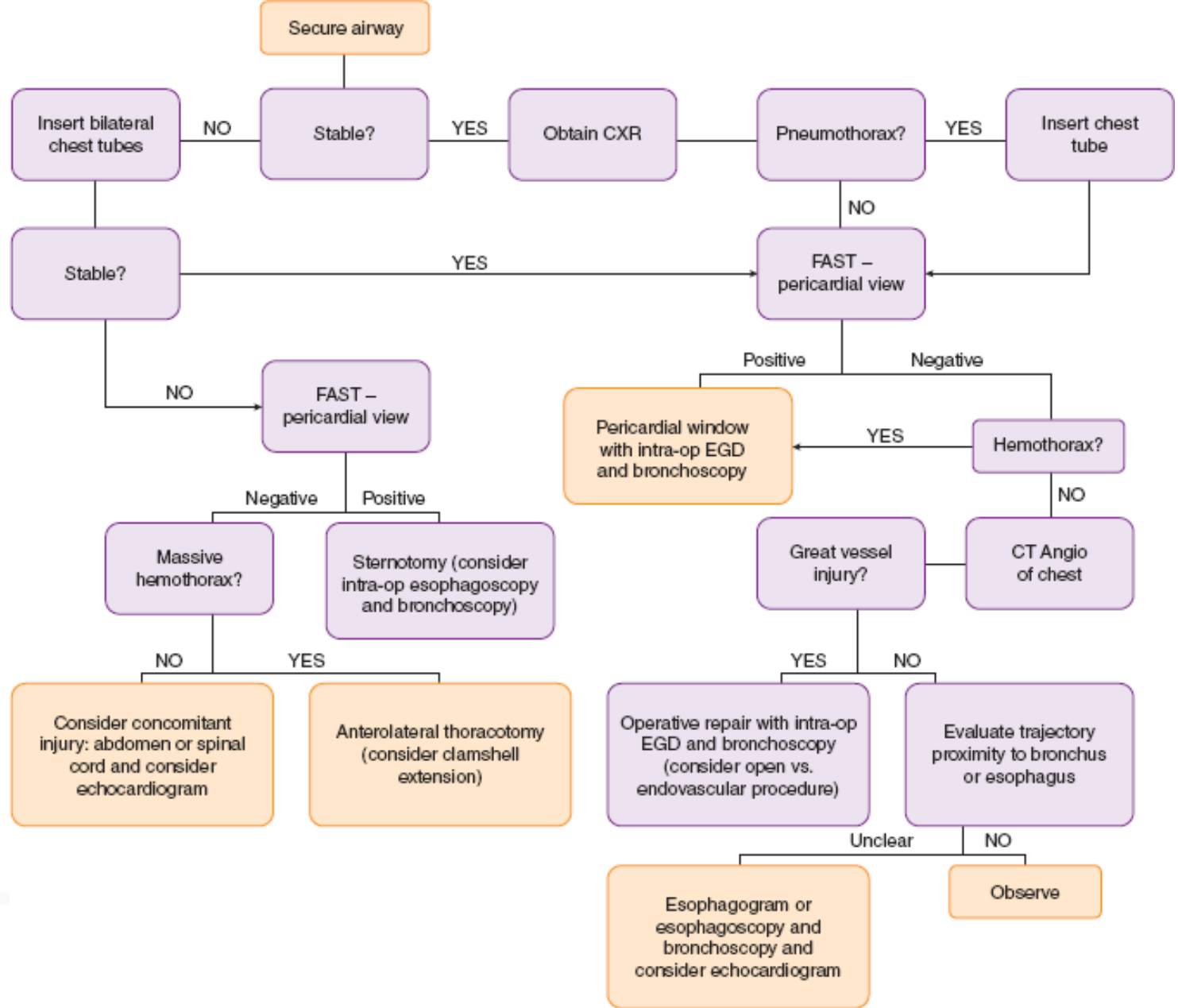


The Athens Crossroad

8-10 November 2018

Zappeion Megaron Hall, Athens





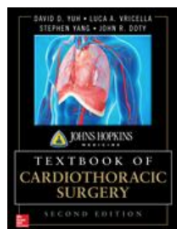
## 2: Thoracic Trauma

George J. Koenig, Jr.; David T. Efron

Sections

Print

Share



# The Athens Crossroad

## 8-10 November 2018

Zappeion Megaron Hall, Athens





- To VATS or not to VATS?
- Hybrid theatres?
- Glasgow Experience  
*(sternotomy training)*
- Greek Experience