



Ch-EVAR

Konstantinos Spanos, MD, MSc, PhD

*Vascular Surgeon, Vascular Surgery
Department,*

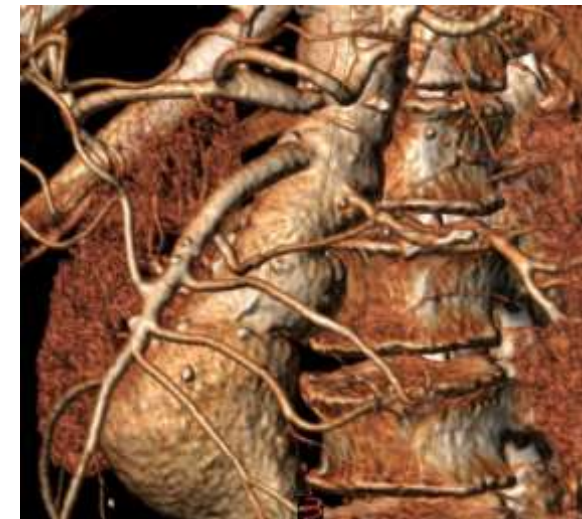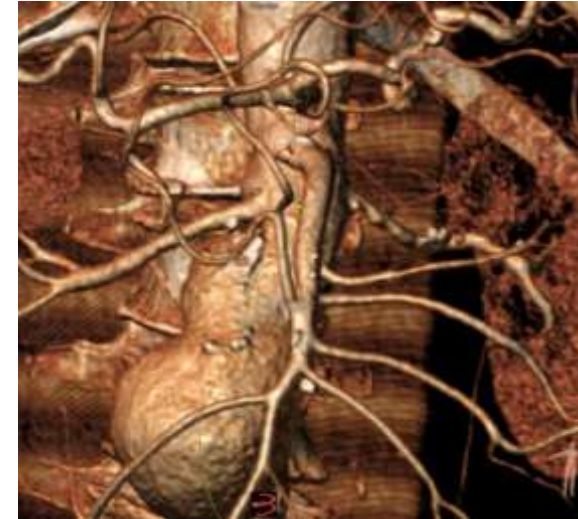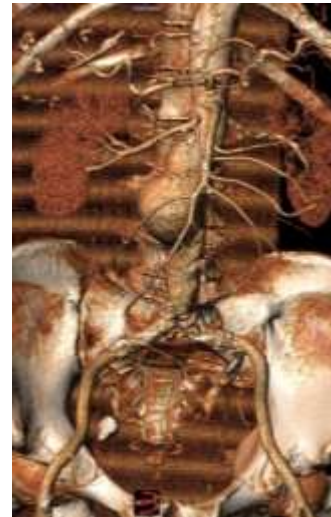University Hospital of Larissa, Larissa, Greece



- ✓ 76 year-old
- ✓ Male
- ✓ Para-renal AAA 95mm

✓ *Medical history significant for*

- Ex-smoker
- Hypertension
- Dyslipidaemia
- CAD (MI 91', Cardiac arrest 91', EF 35%)
- Colectomy (Colon Ca)

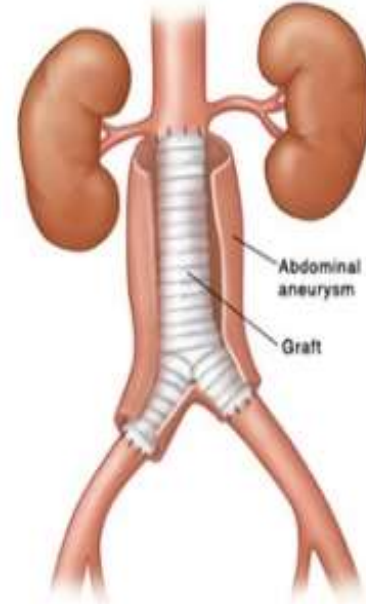
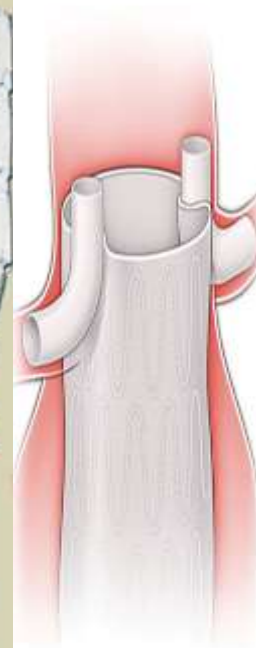
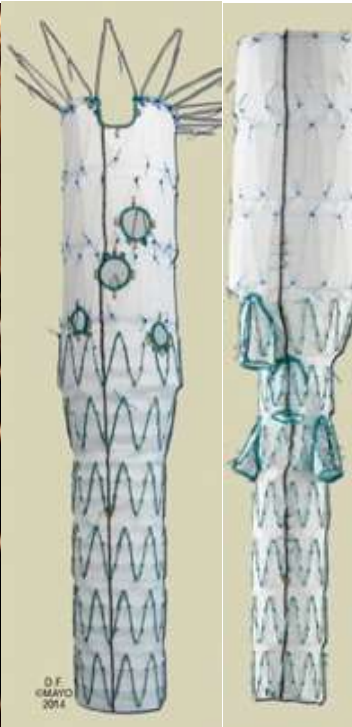
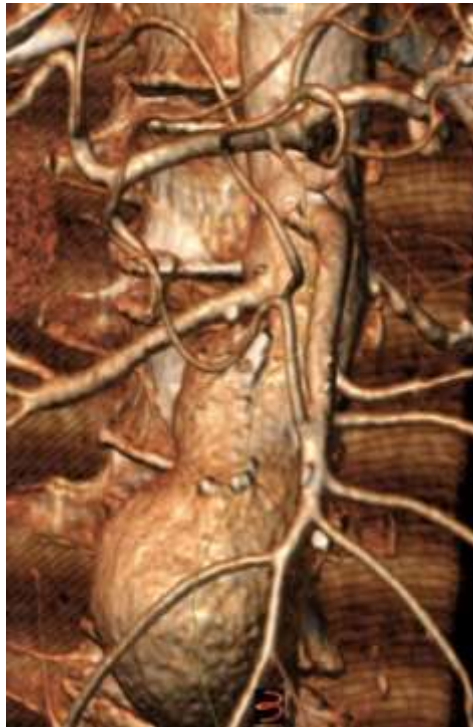


Treatment options



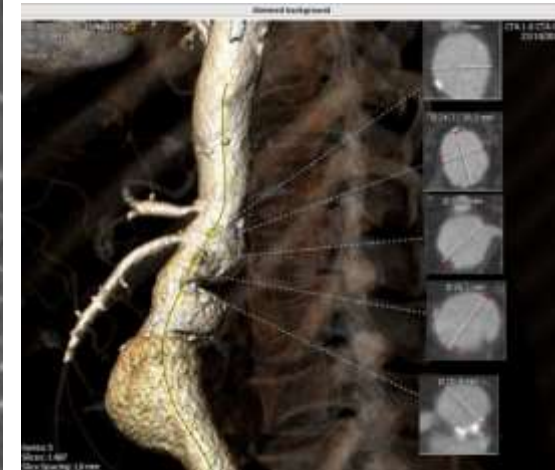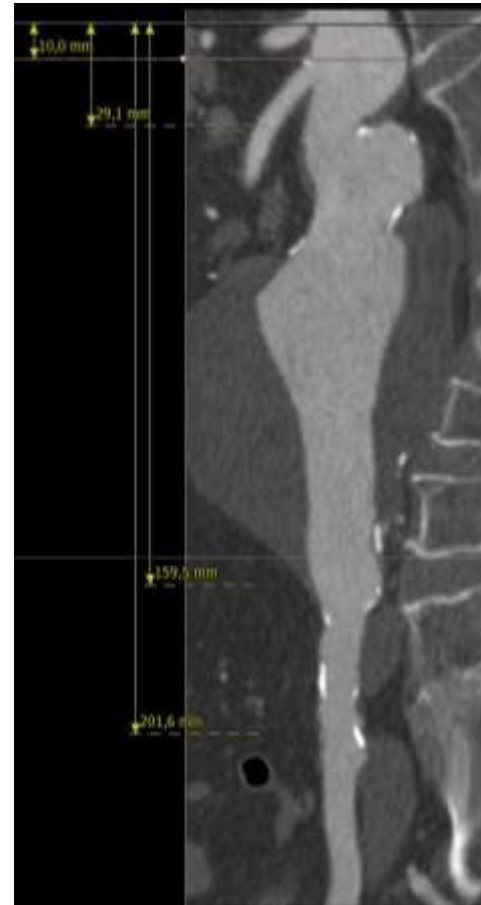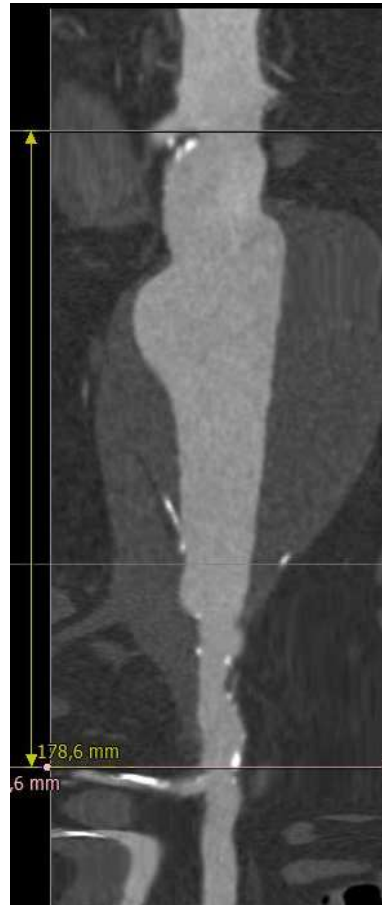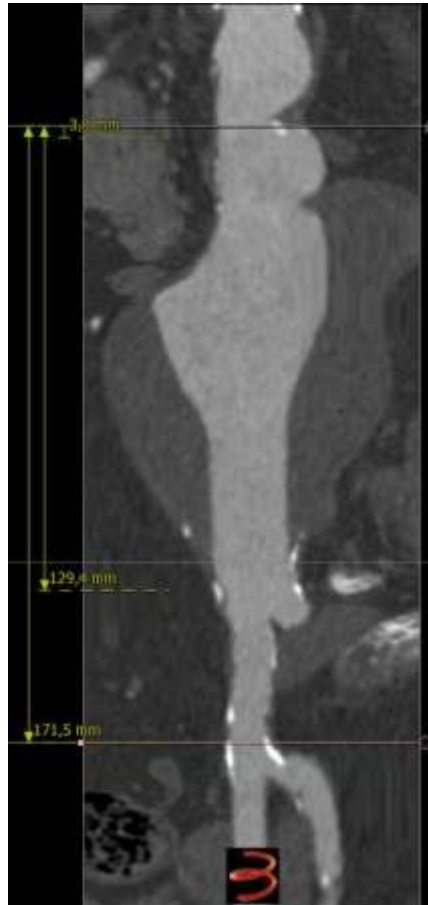✓ Ch-EVAR



Open surgery for an abdominal aortic aneurysm

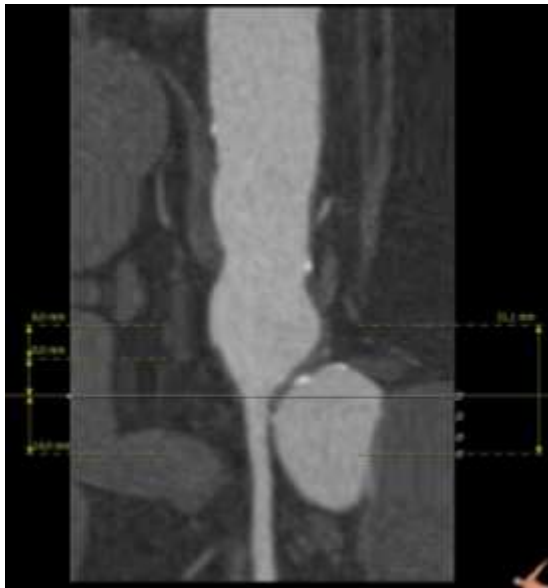

Proximal - Distal Zone

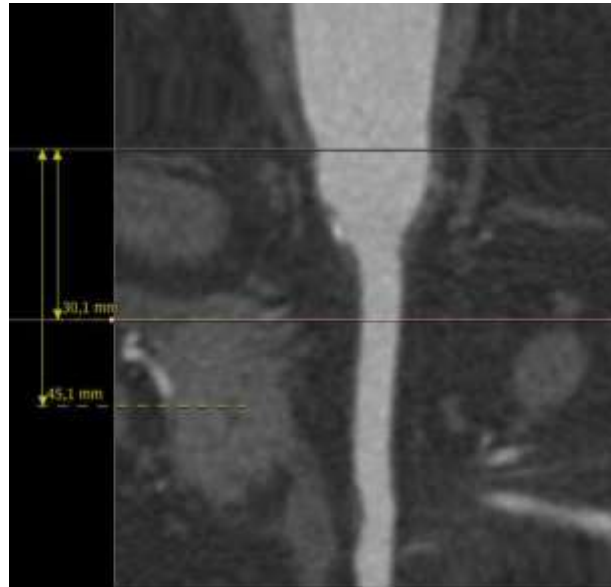




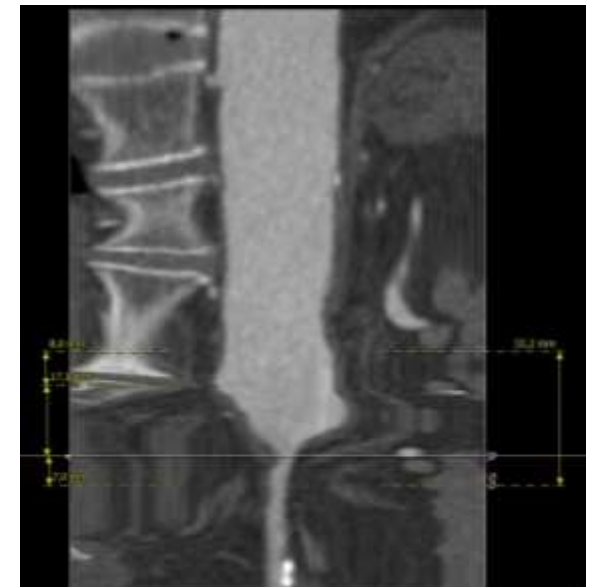Targeted Visceral Vessels



RRA



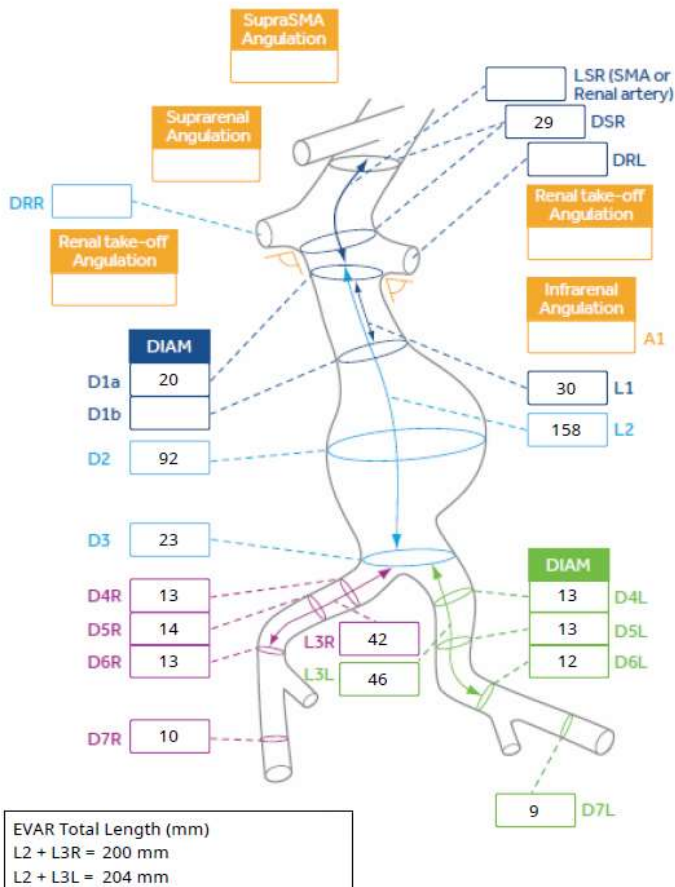
SMA



LRA



Pre-operative Measurements



Chimney EVAR worksheet

Chimneys

Diameter	mm	Diameter	mm
D _a	23.9	d _{ch1}	
D _{ch1}	22.7	d _{ch2}	7.2
D _{ch2}	25.2	d _{ch3}	5.0-6.2
D _{ch3}	16.5	d _{ch4}	5.5
D _{ch4}	23.5		
D _{ch5}	16.6		

CEL:

SMA: BeGraft (8x38), Sx 9x40
 RRA: BeGraft (7 or 6x37), Sx (8 or 7x60)
 LRA: BeGraft (6x 37 or 37), Sx (7x60 or 40)

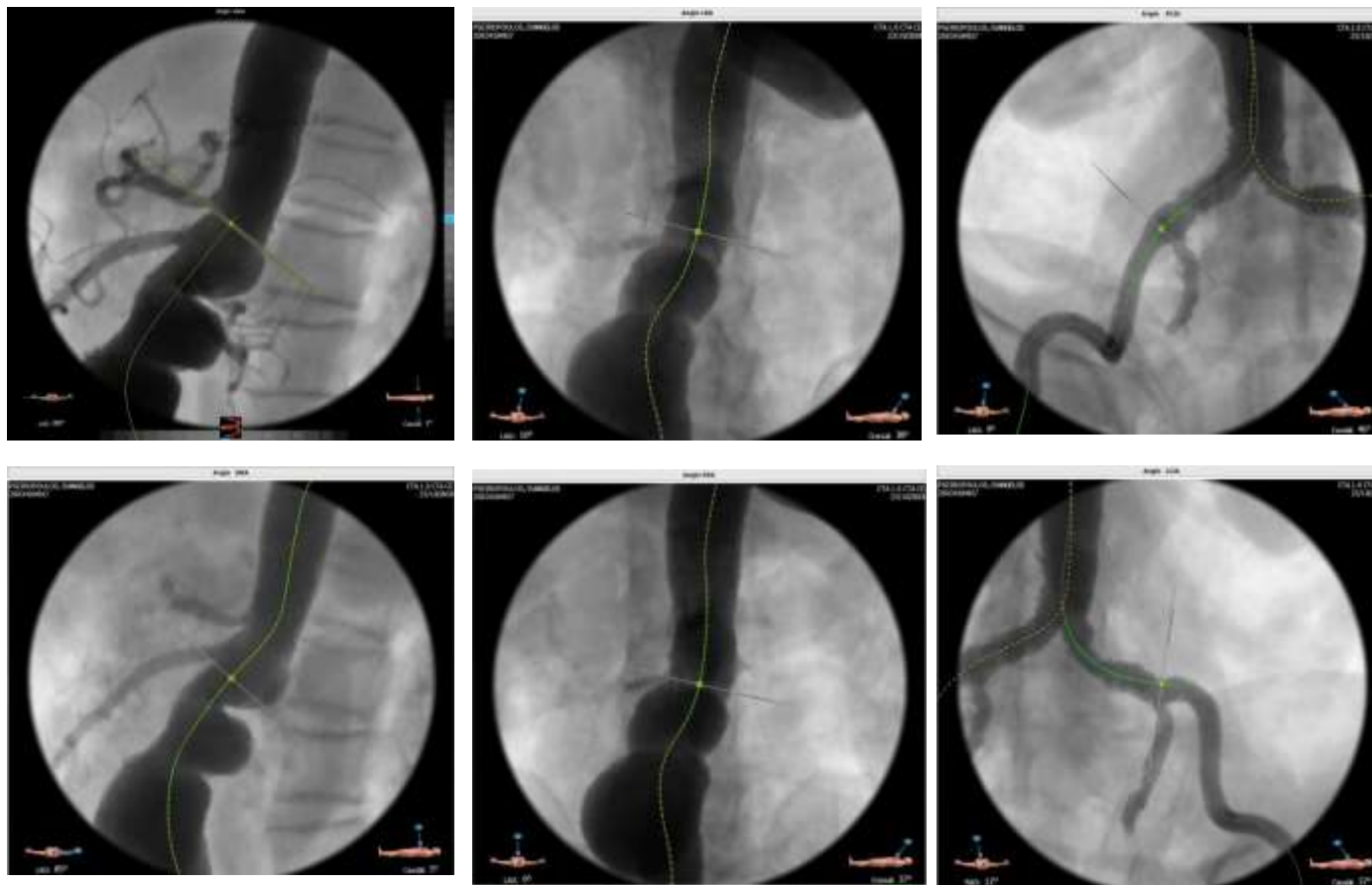
AAA

Measurements	mm	Meas/nts	mm
D1	NA	D9	10.6
D2	NA	D10	10
D3	91		
D4	24	L1	194.4
D5	32.7	L2	202.2
D6	11.2	L3	152.3
D7	12	L4	
D8	12		

Main body: Endurant 36/14/103
 Rt extension: Endurant 16/16/156
 Lt extension: Endurant 16/16/156



Pre-operative Measurements



Planning

Map body arrow: Right Left

Stent landing zone B: 2A

Stent landing zone C: 2A

For mobilization:

Required special material: Teflon, 3 Sizes

www

C-ARM Configuration

CA	LAD 92	Card 1
VB	LAD 88	Card 6
WA	LAD 24	Card 18
LB	BAF 12	Card 28
WB	LAD 27	Card 40
SB	BAF 37	Card 50

Intra-operative details

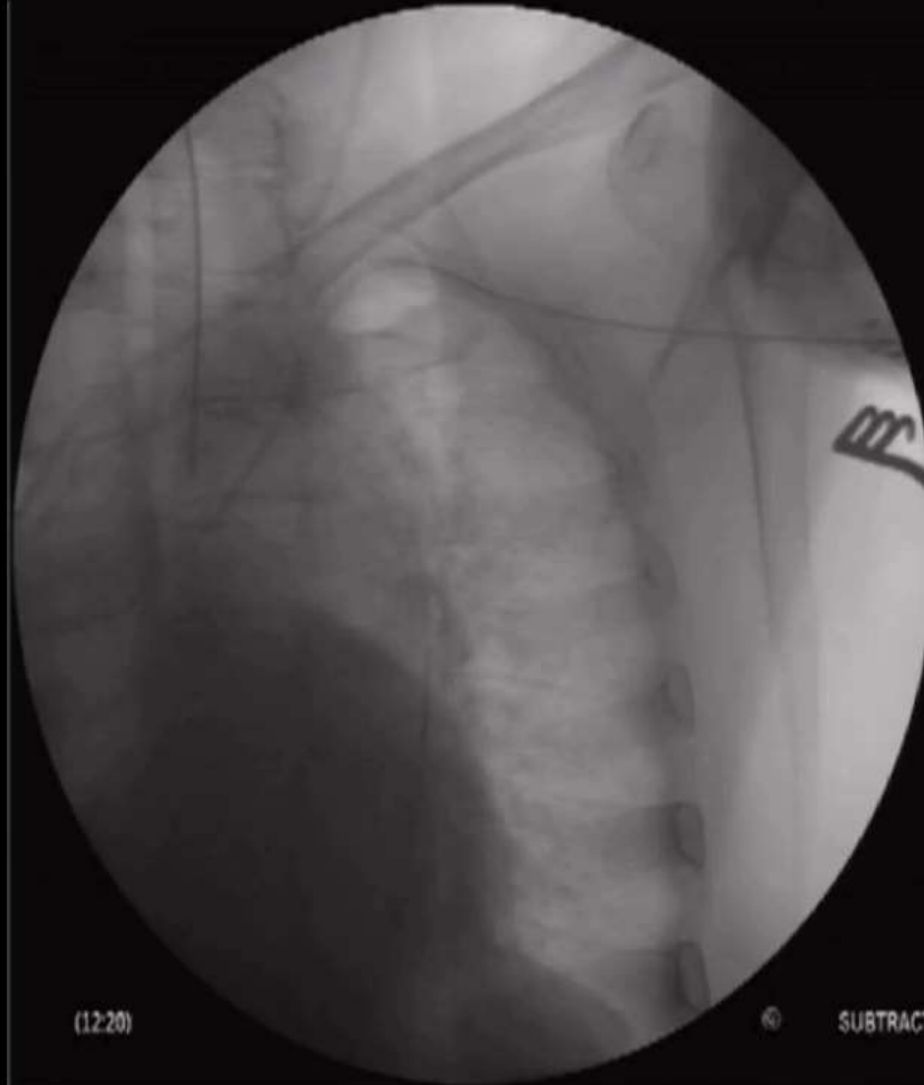
➤ *Intra-operative data*

- ✓ Duration of operation 240min
- ✓ No changes in INVOS
- ✓ 5000ui Heparin + 2500ui Heparin (after 2^{1/2} h, ACT 198)
- ✓ 2 FBC
- ✓ Contrast 160ml
- ✓ Radiation 493mGy (50min)



Patient transferred to ward under close monitoring

No need for ICU



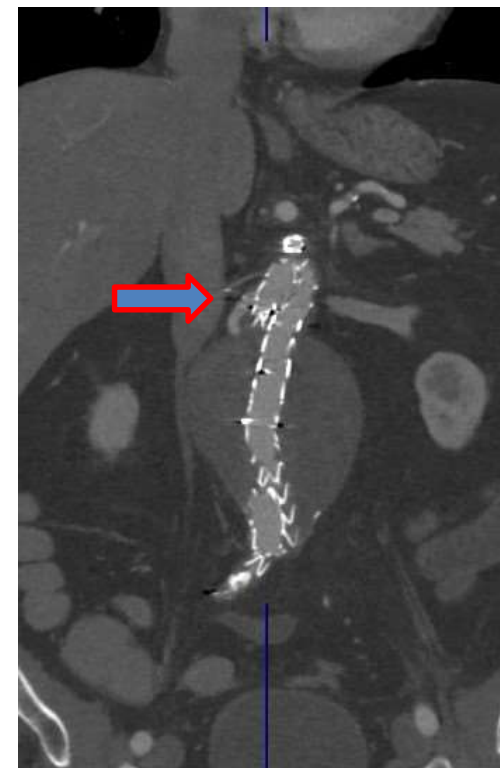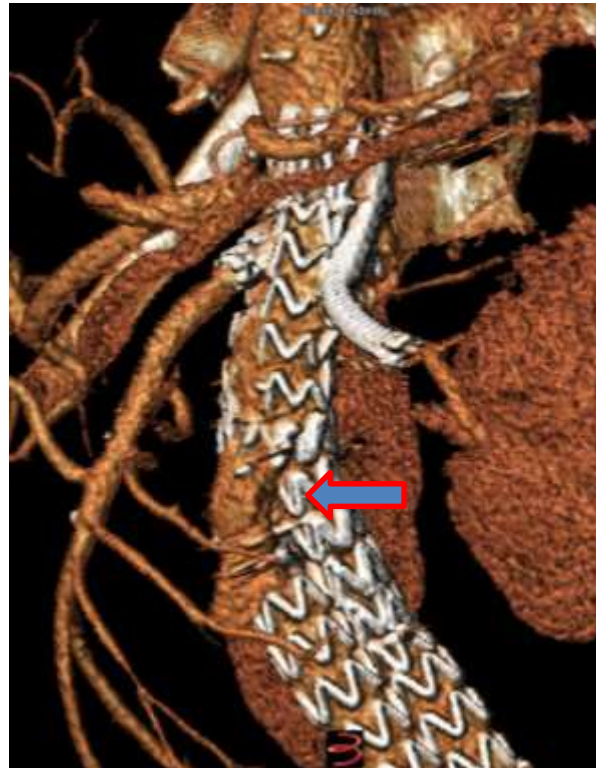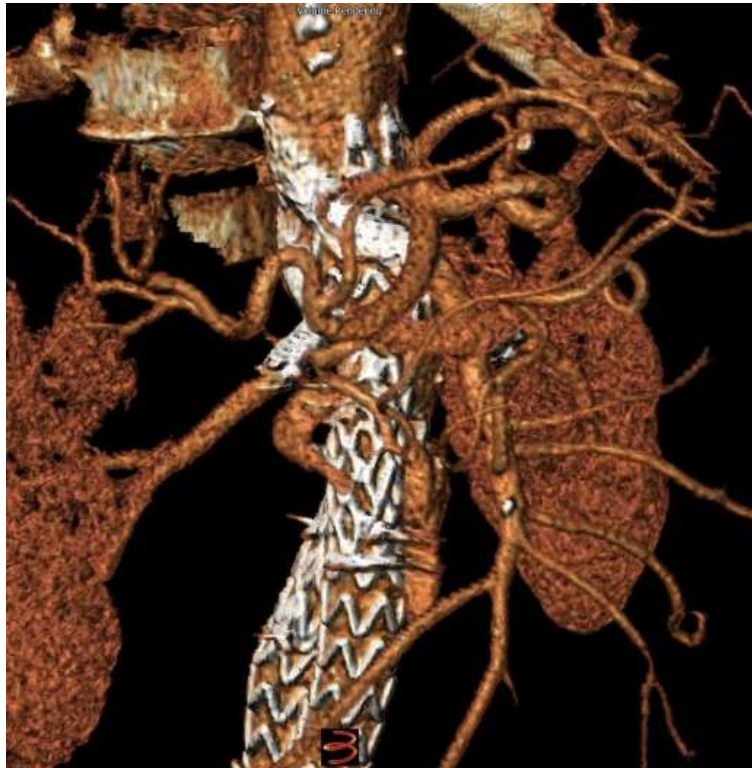(12:20)



SUBTRACT

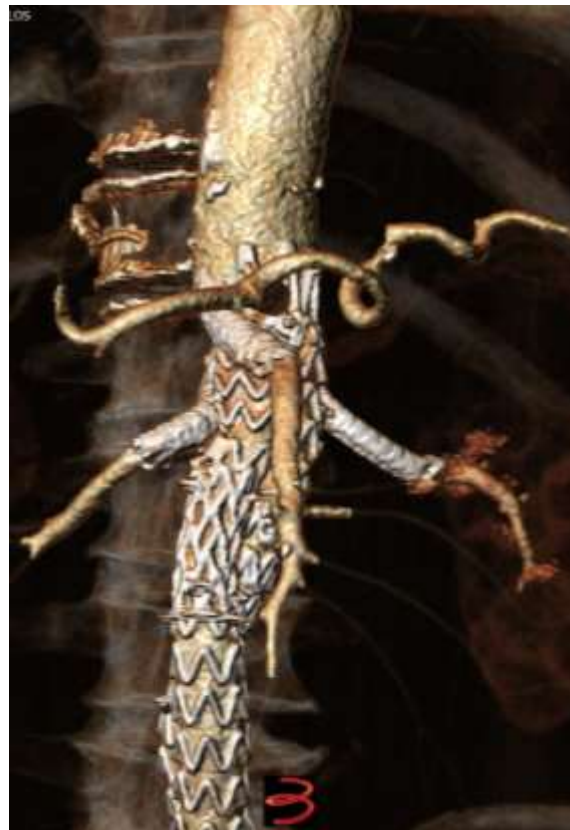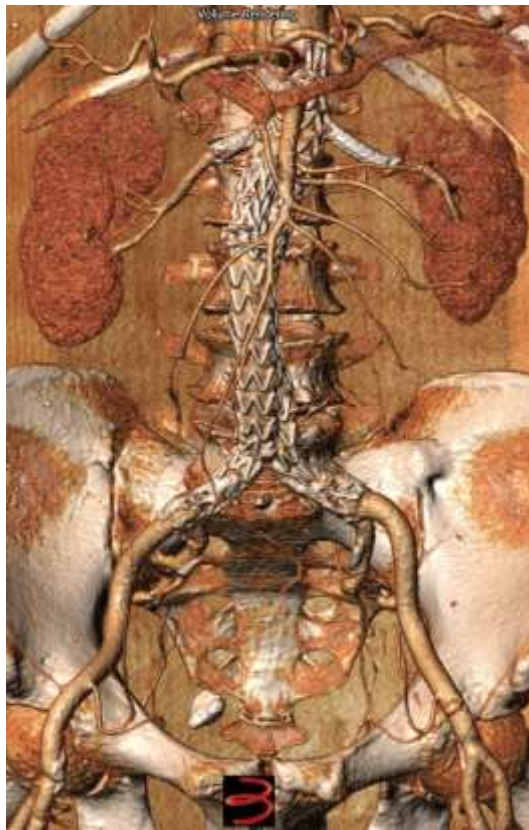


Immediately Post-op



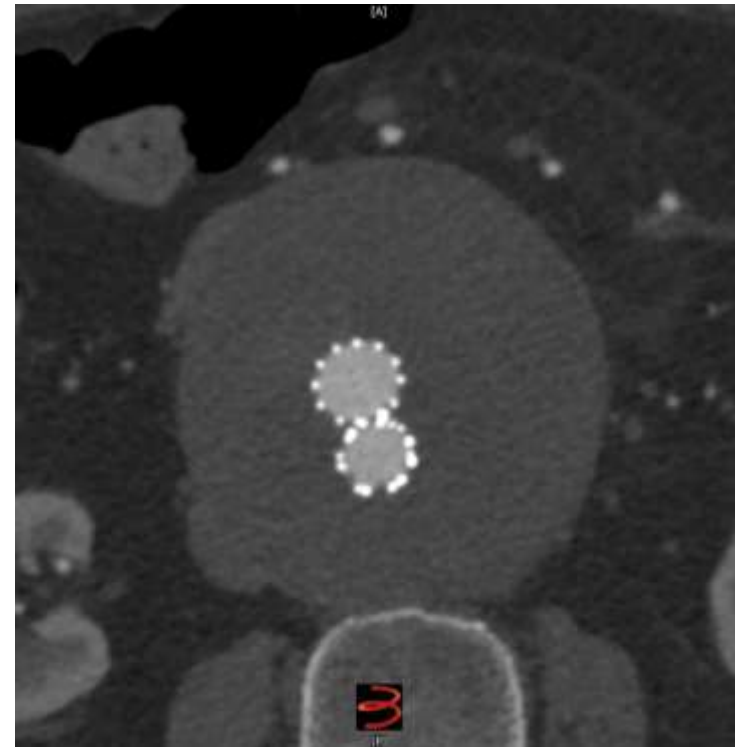
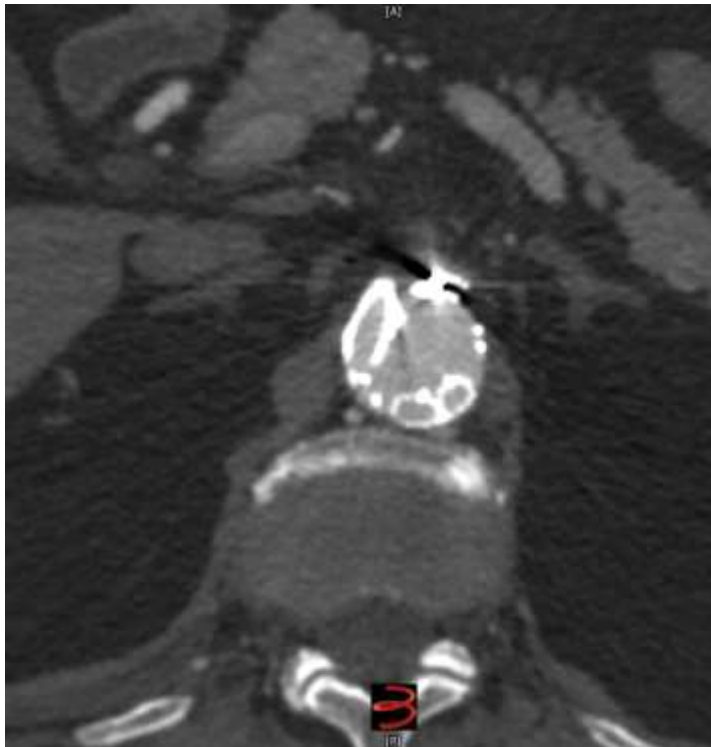


1st month Post-op



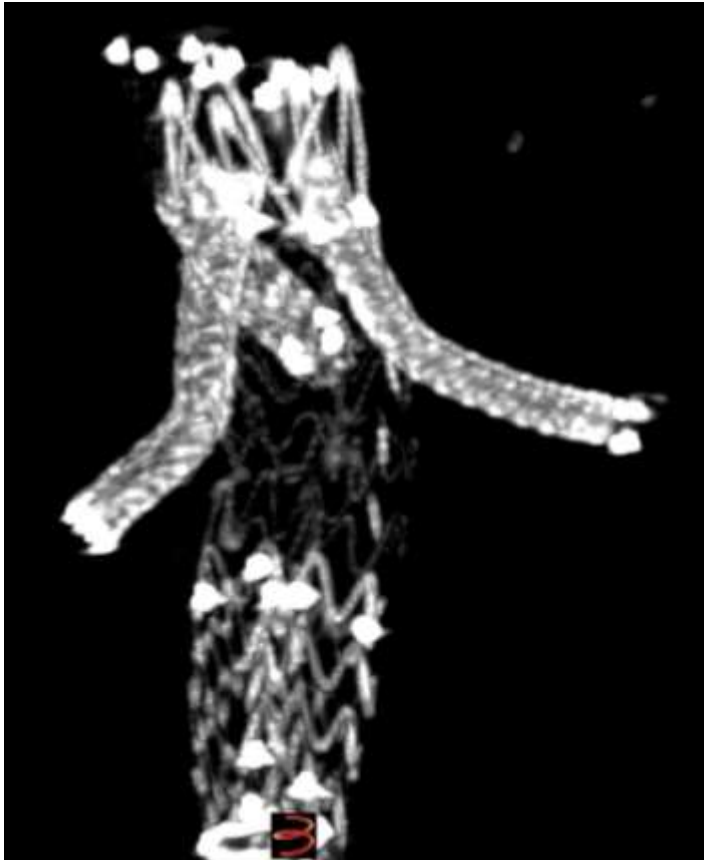

1st month Post-op





1st month Post-op





Thank you

