



**ATHENS MEDICAL
GROUP**

Athens Medical Center



Urgent total endovascular repair of the aortic arch with chimney and periscope technique

Theodosios Bisdas, MD, PhD

Associate Professor for Vascular Surgery

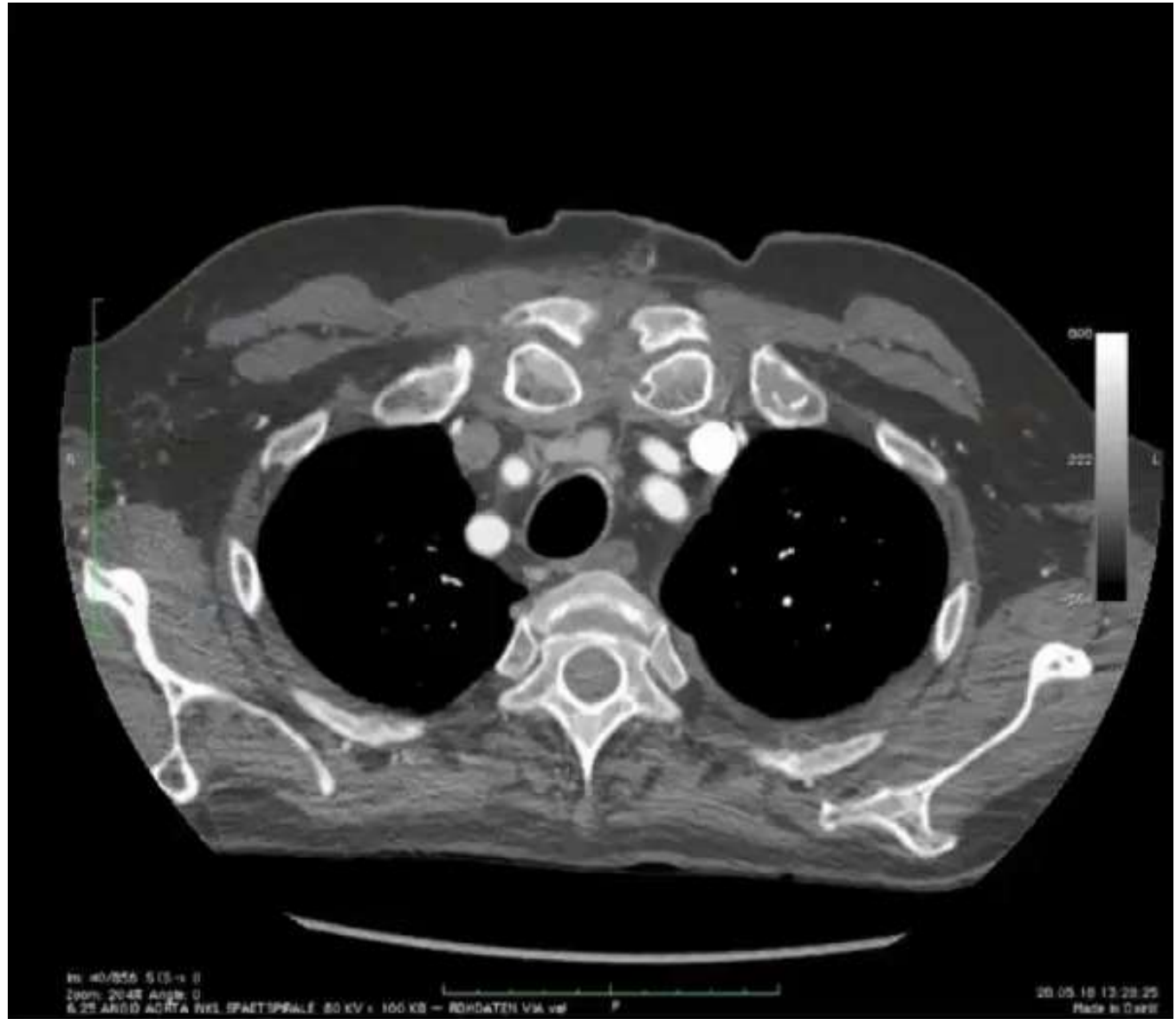Founder of Vascupedia

Athens Medical Center

Athens, Greece

Case presentation

- 78 years old male
- AH, COPD, CAD, PAD, Smoker
- Previous replacement of the ascending aorta due to type A aortic dissection
- Current symptoms (one month later)
 - Persistent hypertension (5 medis)
 - Multiple TIAs



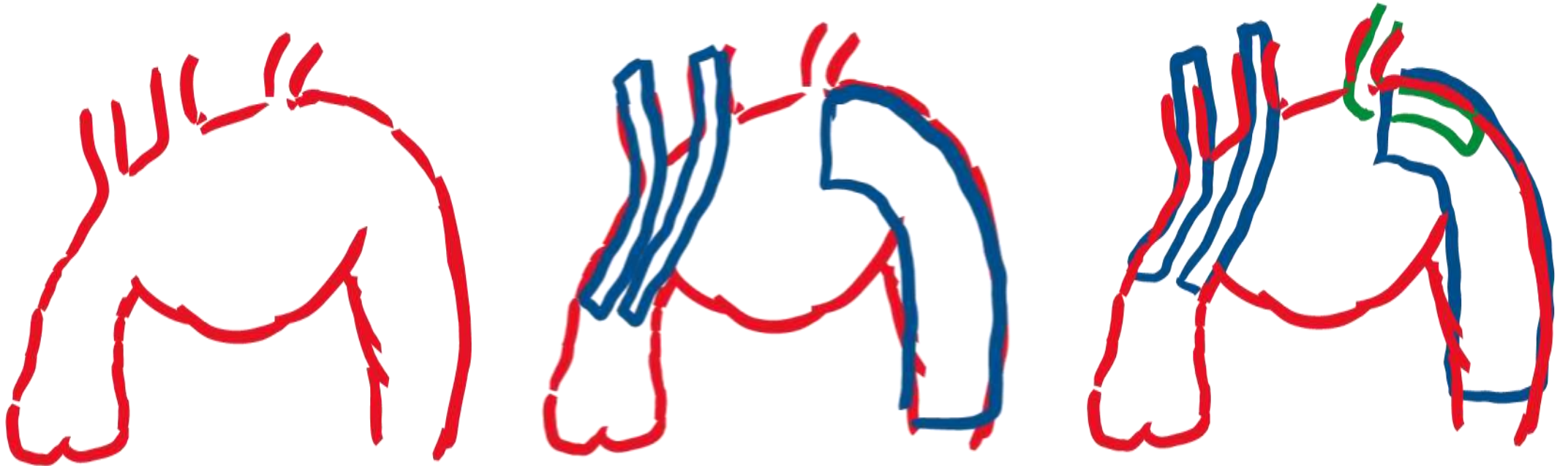
Treatment strategies

- Conservative
- Open surgery (Redo)
- Endovascular treatment
 - Custom-made
 - Off-the-shelf

Treatment strategies

- Conservative
- Open surgery (Redo)
- Endovascular treatment
 - Custom-made
 - Off-the-shelf

The combined chimney and periscope technique



The combined chimney and periscope technique

