

# ENDOVASCULAR CORRECTION OF THORACOABDOMINAL ANEURYSM: CASE REPORT

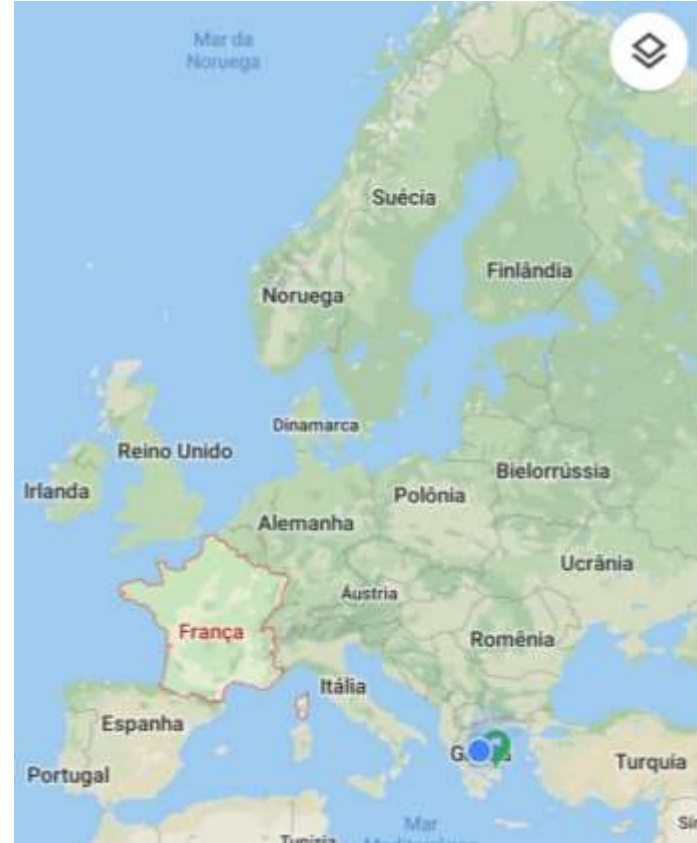
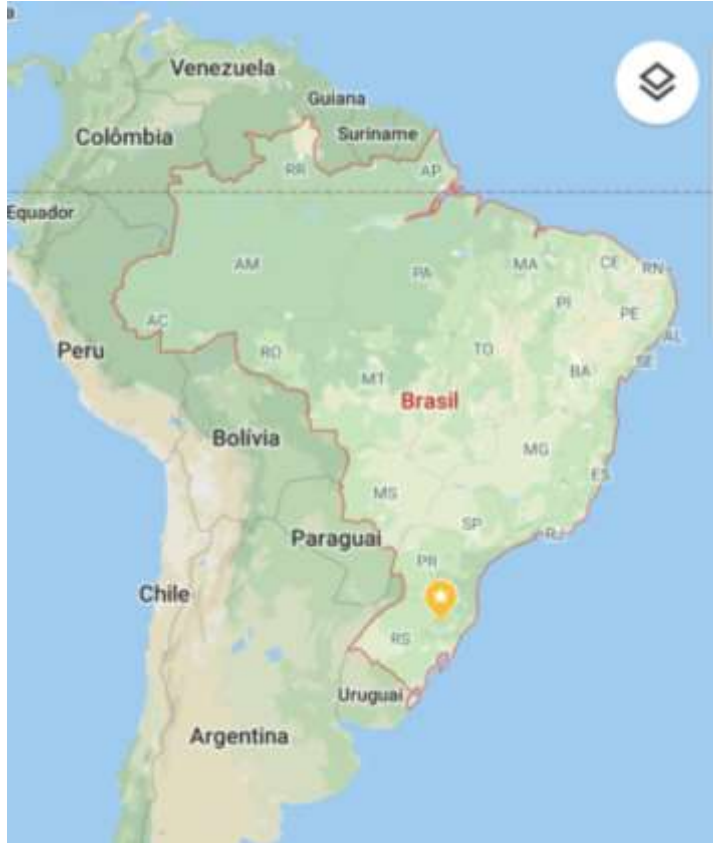Mariana Vetturazzi

University of Caxias do Sul

General Hospital of Caxias do Sul

Roberto Heck, Clandio F Dutra, Vinicius Lain

Service of Vascular Surgery University of Caxias do Sul



**LIVE** 2019  
Leading  
Innovative  
Vascular  
Education

**May 9-11 2019**

Larissa Imperial Hotel  
Larissa, GREECE

<http://www.live2019.gr>

Organized by:



Institute of Vascular  
Diseases (IVD), Greece

In collaboration with:



Hellenic Society of Vascular and Endovascular Surgery



Stony Brook University Medical Center, New York, USA



International Symposium on Endovascular Therapeutics



Intervention Master Aortic Course

**10<sup>th</sup>**  
ANNIVERSARY



 **UCS**  
UNIVERSIDADE  
DE CAXIAS DO SUL



## CASE REPORT

S. V. G. C., female, 59 years old.

14/02/2017

- First consultation:
  - Previously hypertensive patient diagnosed with thoracoabdominal aneurysm during investigation of renal colic pain;
  - She denied abdominal pain or any other symptom related to aneurysm.

## CASE REPORT

14/02/2017

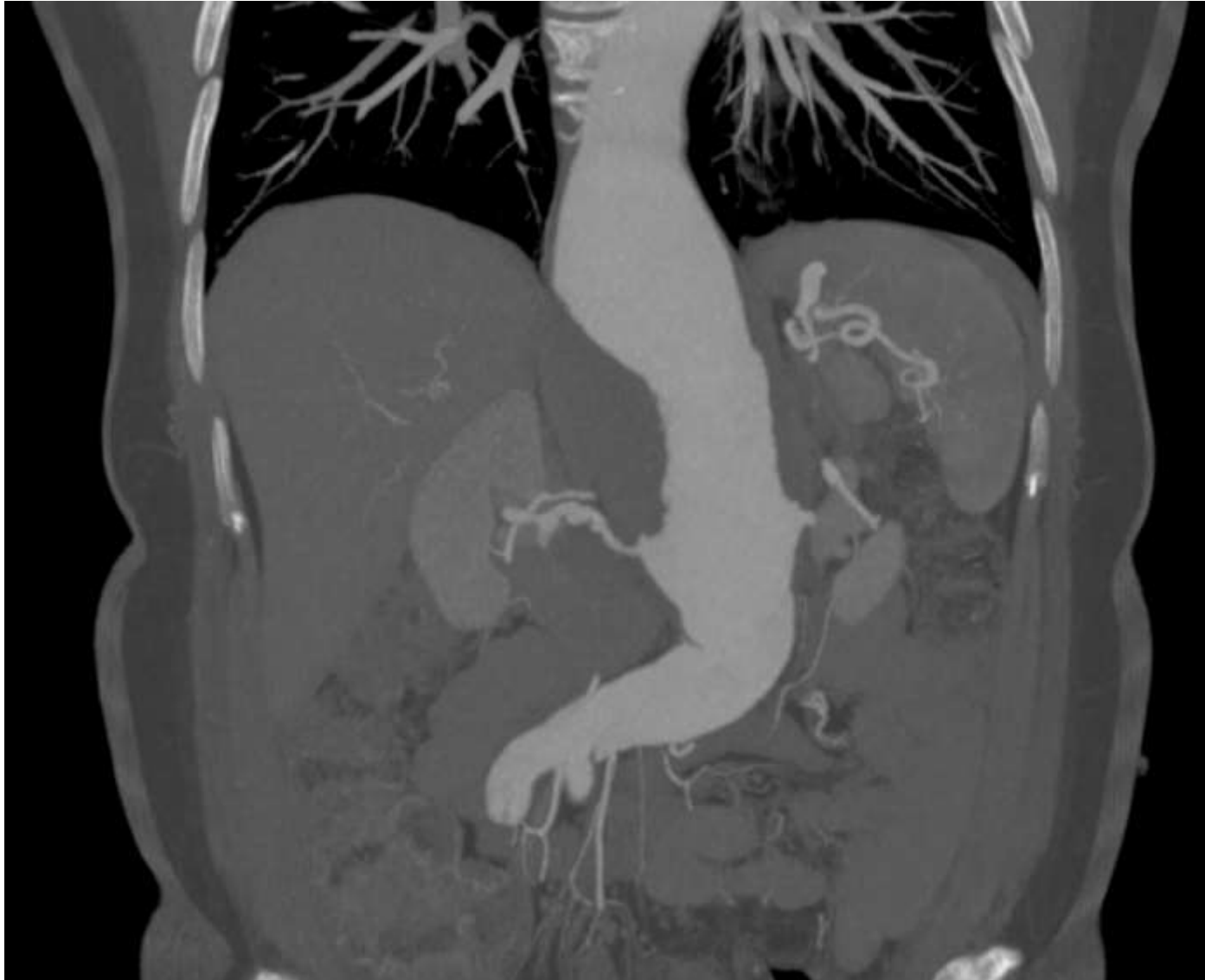- First consultation:
  - Physical examination:
    - ABD: flat, symmetric, painless palpation and no signs of peritoneal irritation.  
Presence of pulsatile mass;
    - Extremities: pulses present and full.



## CASE REPORT

21/11/2017

- Previously to first consultation:
  - Angiotomography:
    - Fusiform aneurysmatic dilatation of the thoracoabdominal transition;
    - It was observed in the distal segment and along the common iliac arteries linear imaging of double lumen, characterizing dissection;
    - Secular aneurysmatic dilatation of right renal artery.



**May 9-11 2019**

**Larissa Imperial Hotel  
Larissa, GREECE**

<http://www.live2019.gr>

Organized by:



**Institute of Vascular  
Diseases (IVD), Greece**

In collaboration with:



Hellenic Society of Vascular and Endovascular Surgery



Stony Brook University Medical Center, New York, USA

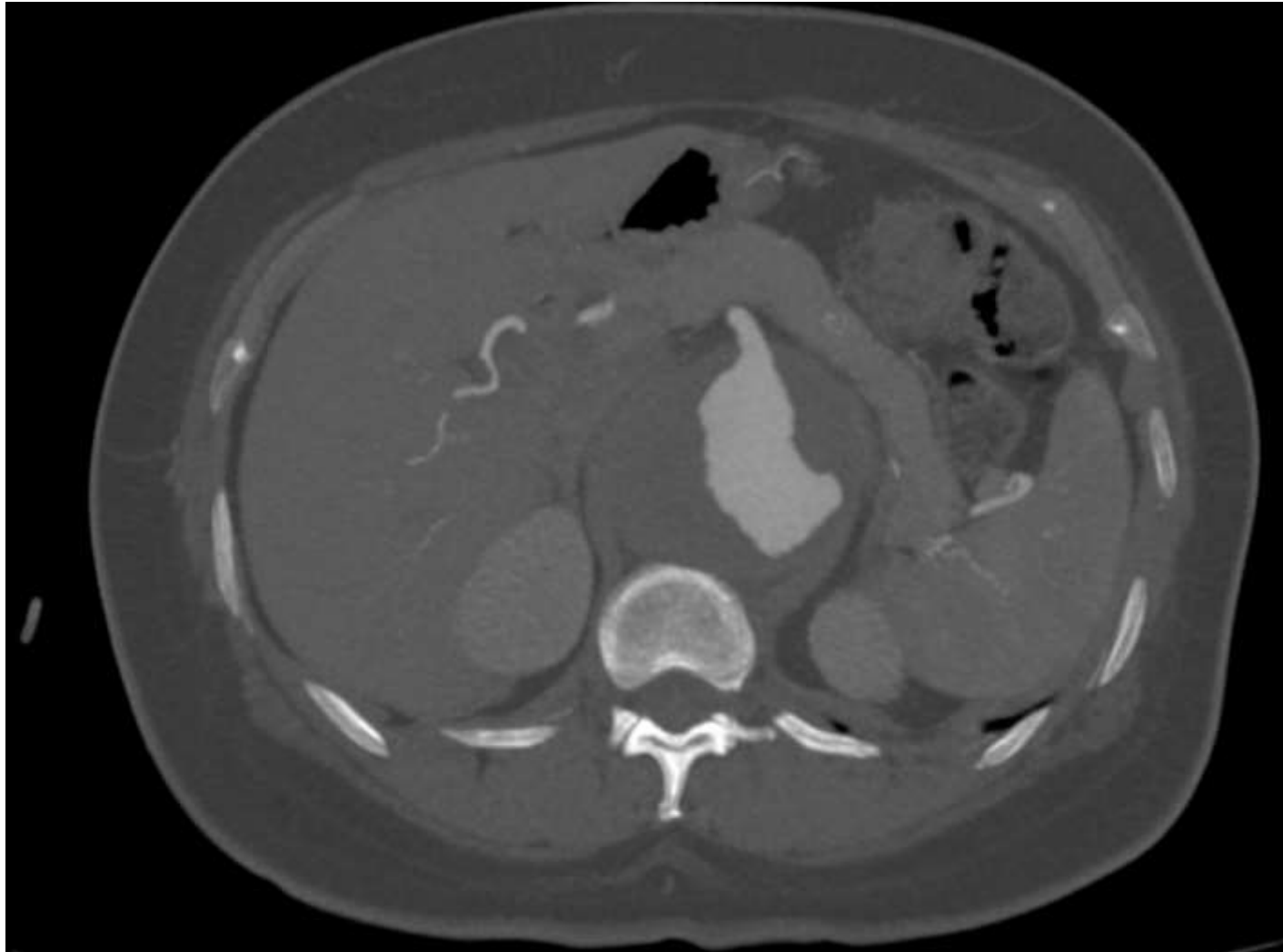


International Symposium on Endovascular Therapeutics

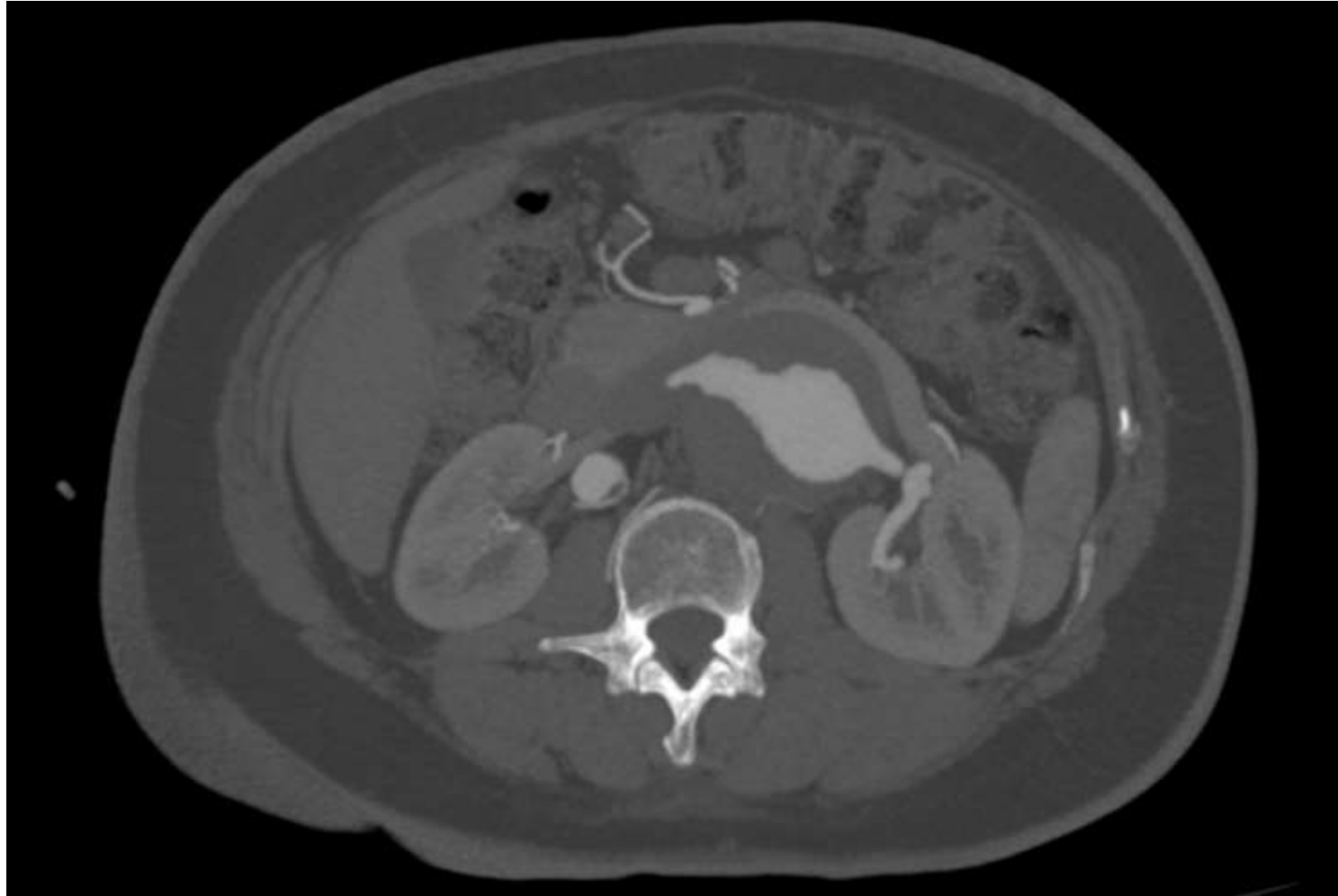

Intervention Master Aortic Course

**10<sup>th</sup>**  
ANNIVERSARY







**May 9-11 2019**

**Larissa Imperial Hotel  
Larissa, GREECE**

<http://www.live2019.gr>

Organized by:



**Institute of Vascular  
Diseases (IVD), Greece**

In collaboration with:



Hellenic Society of Vascular and Endovascular Surgery



Stony Brook University Medical Center, New York, USA



International Symposium on Endovascular Therapeutics



Intervention Master Aortic Course



## CASE REPORT

- Conduct:
  - Plan of endovascular correction;
  - Two times to avoid possible paraplegie by occlusion of medular branches.

## CASE REPORT

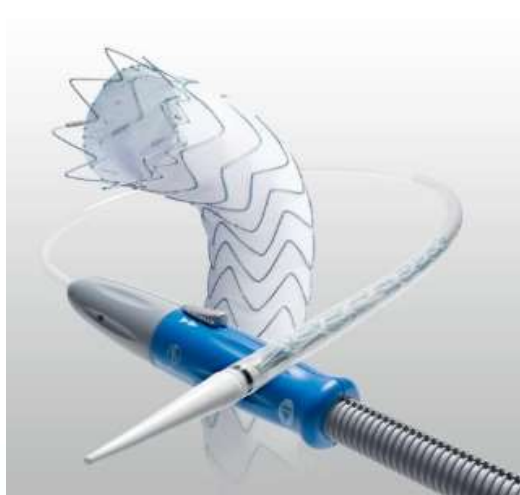15/03/18:

- Patient submitted to thoracic endovascular aortic repair (TEVAR) with stent-graft (Valiant Captiva, Medtronic Vascular®, Santa Rosa, CA, Estados Unidos da América) for three branches:
  - Superior mesenteric artery (SMA);
  - Left renal artery (LRN);
  - Right renal artery (RRA).

## CASE REPORT

15/03/18:

- Valiant Captiva 34x34x212 with ramifications to SMA, LRN, RRA;
- Nester fiber coil 4x14 mm divided between the three branches for arterial embolization.



## CASE REPORT

15/03/2019

- Procedure:

- Dissection of the right inguinal region;
- Punction of left superior femoral artery with placing of 8F introducer and puction of right braquial with 5F introducer;
- Partial liberation of graft-stent in thoracic aorta;
- Selective catheterization by retrograde direction of superior mesenteric artery;
- Liberation of graft-stent by selective catheterization of left renal artery and right renal artery.
- Revestid graft-stent in SMA (v12 7x38) /
- LRA (v12 5x38) / RRA (v12 6x38).



**May 9-11 2019**

**Larissa Imperial Hotel  
Larissa, GREECE**

<http://www.live2019.gr>

Organized by:



**Institute of Vascular  
Diseases (IVD), Greece**

In collaboration with:



Hellenic Society of Vascular and Endovascular Surgery



Stony Brook University Medical Center, New York, USA

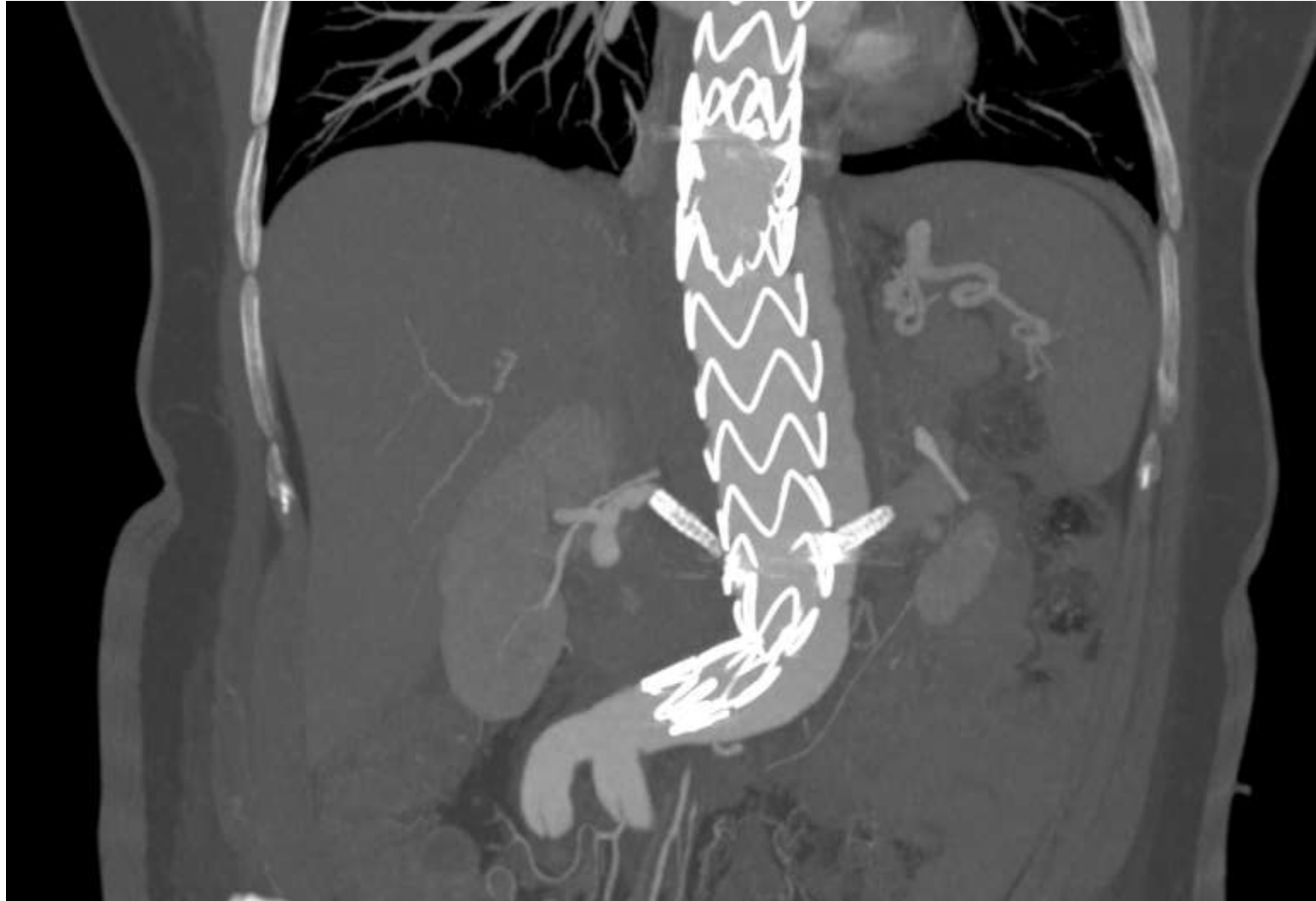

International Symposium on Endovascular Therapeutics



Intervention Master Aortic Course

**10<sup>th</sup>**  
ANNIVERSARY



## CASE REPORT

21/05/2018:

- Patient submitted to implantation of infrarenal bifurcated graft-stent Endurant II.
- Confection of the endograft Endurant II 36x36x145 mm without free flow and with reduction of two proximal stents.



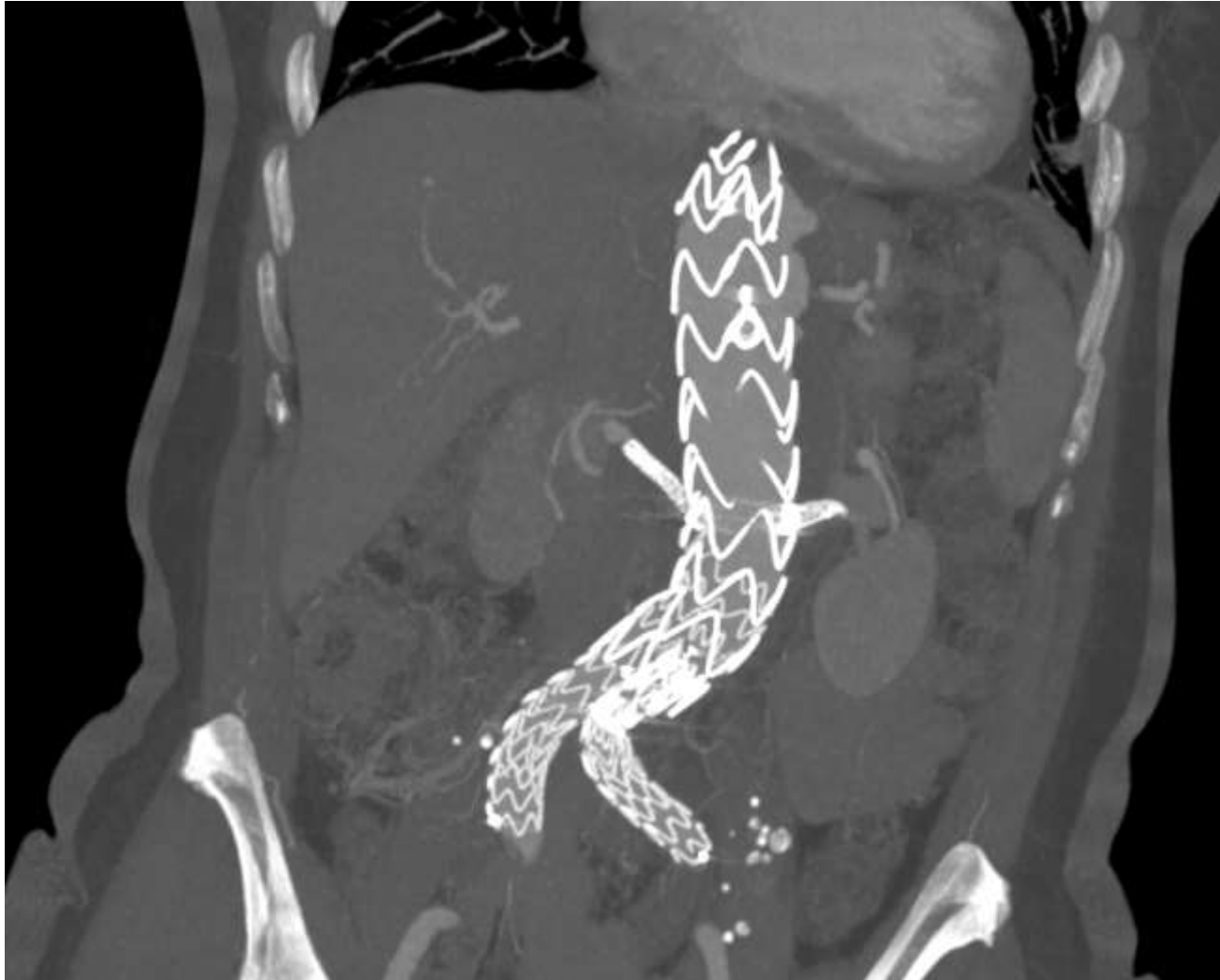ENDURANT II STENT GRAFT

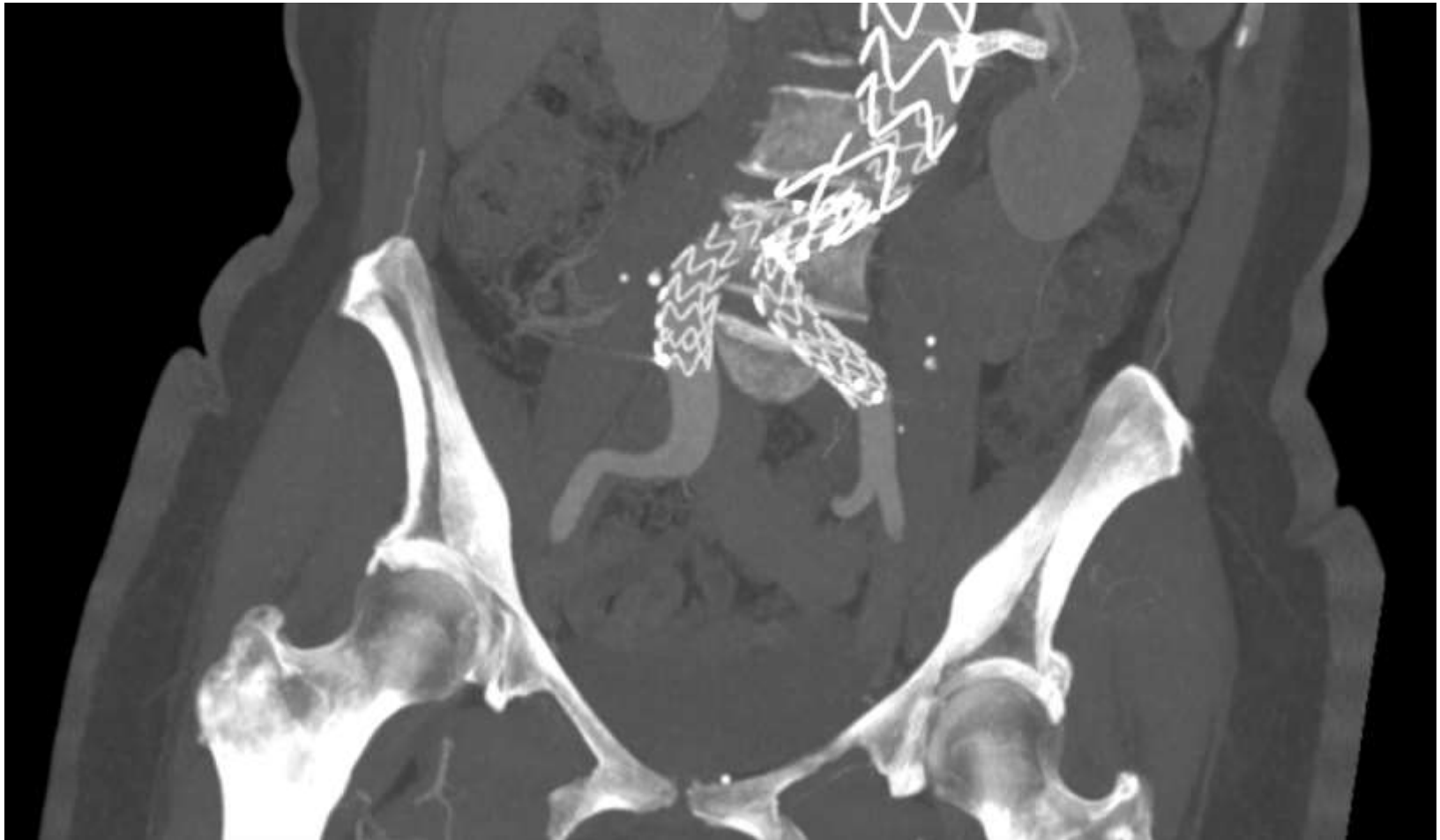
## CASE REPORT

21/05/2018

- Procedure:

- Dissection of right inguinal region;
- Punction of left superior femoral artery;
- Implantation of bifurcated graft-stent Endurant II and extension to left 16x13x93mm.







## CASE REPORT

- Follow up:
  - Patient came back to the consultation with endoleak type III by fenestration of superior mesenteric artery.
- Conduct:
  - Embolization of endoleak and planning of correction of secular aneurysm of right renal artery.



## CASE REPORT

14/02/19:

- Endoleak type III flow by branch of superior mesenteric artery;
- Endoleak type II backflow by occlusion of celiac trunk.

## CASE REPORT

14/02/19:

- Procedure:

- Punction of left braquial artery with introducer 5F and after introducer 8F;
- Catheterization of the superior mesenteric artery with implantation of revestid graft-stent v12 9x38 and Lefestream 9x39. Procedure realized successfully;
- Catheterization of the pancreatoduodenal branch of the mesenteric superior artery with microcatheter and identification of anastomotic branch with the celiac trunk that caused the endoleak type II;
- Embolization of the aneurismatic sac with Onyx (7 units).



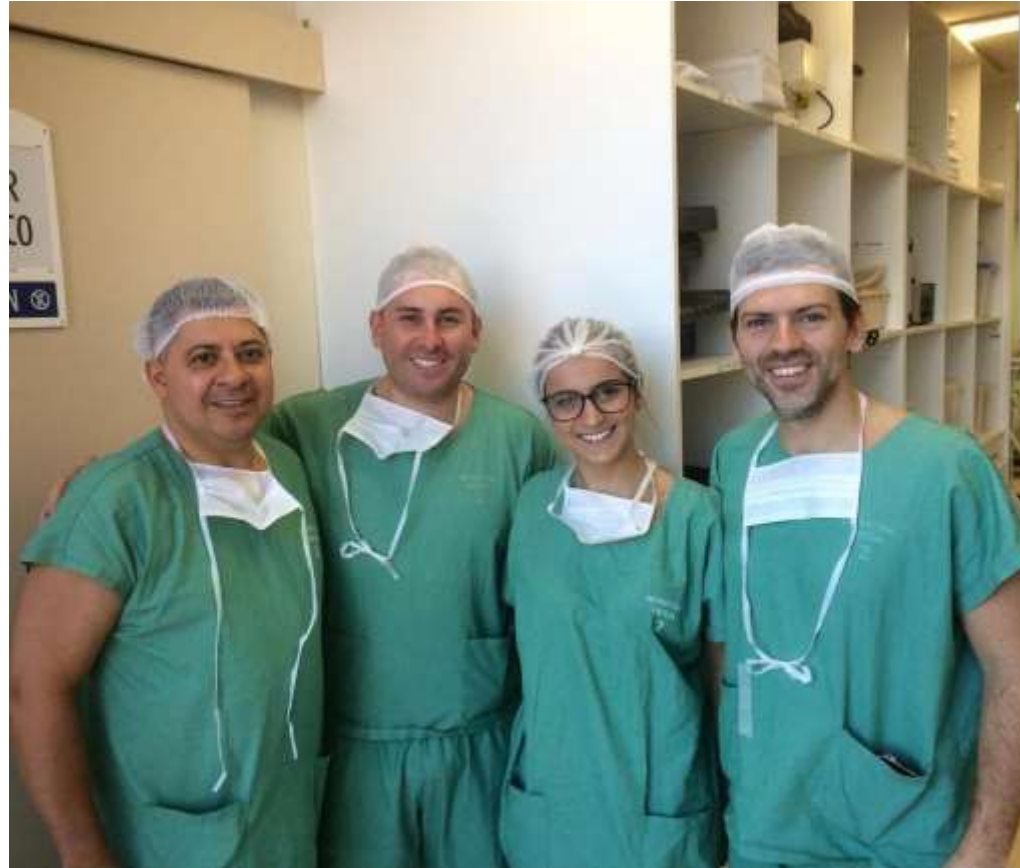## CASE REPORT

- Patient's perspective:
  - Following the intervention our patient said that he had not believed that his condition would be treated so easily and she had expected a huge open surgery.

## CONCLUSION

- Endovascular techniques for the treatment of thoracoabdominal aneurysms are not yet widely used due to limitations associated with them such as spinal (3-11%) and visceral ischemia;
- The improvement of materials and techniques of endovascular treatment made it possible to repair thoracoabdominal aneurysms through the use of endografts (stent) customized for each patient;
- Endografts are not still reality for all patients due its costs.





**May 9-11 2019**

Larissa Imperial Hotel  
Larissa, GREECE

<http://www.live2019.gr>

Organized by:



Institute of Vascular  
Diseases (IVD), Greece

In collaboration with:



Hellenic Society of Vascular and Endovascular Surgery



Stony Brook University Medical Center, New York, USA



International Symposium on Endovascular Therapeutics



Intervention Master Aortic Course

**10<sup>th</sup>**  
ANNIVERSARY



*Thank you*

Contact information:

Mariana Vetturazzi

[marivettu@gmail.com](mailto:marivettu@gmail.com)

University of Caxias do Sul

Caxias do Sul, RS – Brasil.

