




ΕΛΛΗΝΙΚΗ ΚΑΡΔΙΟΛΟΓΙΚΗ ΕΤΑΙΡΕΙΑ

**ΠΑΝΕΛΛΗΝΙΑ ΣΕΜΙΝΑΡΙΑ
ΟΜΑΔΩΝ ΕΡΓΑΣΙΑΣ | 2018**

8-10 ΦΕΒΡΟΥΑΡΙΟΥ | ΘΕΣΣΑΛΟΝΙΚΗ
ΞΕΝΟΔΟΧΕΙΟ ΜΑΚΕΔΟΝΙΑ PALACE



ΕΛΛΗΝΙΚΗ ΚΑΡΔΙΟΛΟΓΙΚΗ ΕΤΑΙΡΕΙΑ

ΠΟΤΑΜΙΑΝΟΥ 6, 115 28 ΑΘΗΝΑ / Τ. 210 7258003, 006 / Φ. 210 7226139

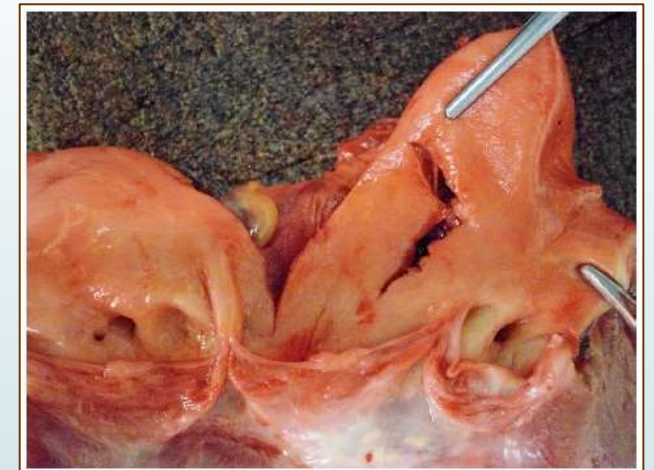
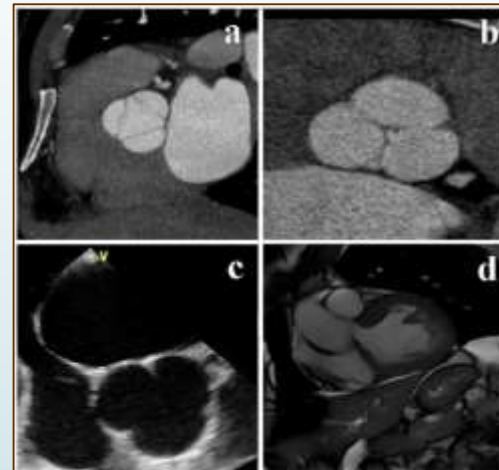
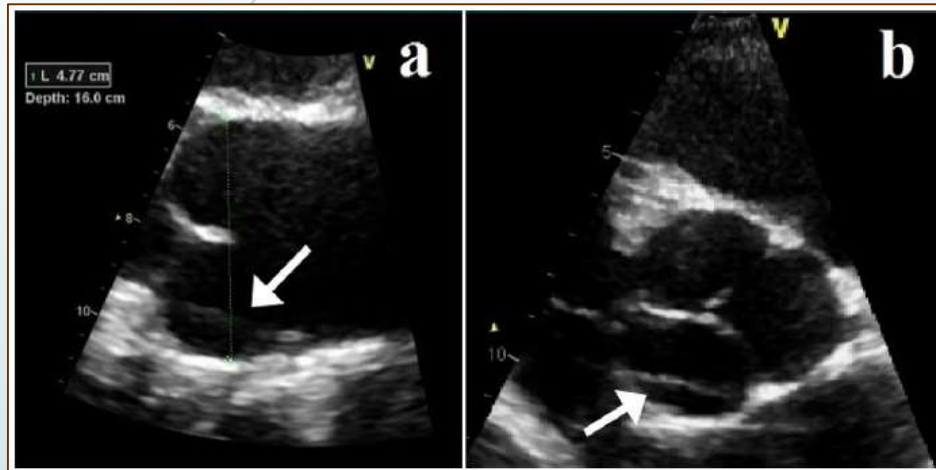
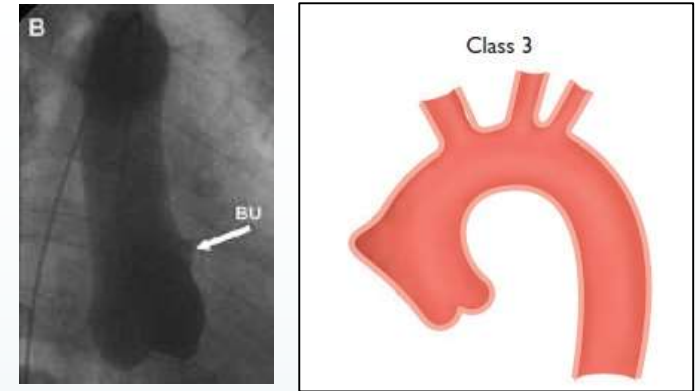
geohcs@hcs.gr / info@hcs.gr / www.hcs.gr

Οξέα αορτικά σύνδρομα και Μυοκαρδιοπάθειες

Είναι αρκετή η
υπερηχοκαρδιογραφική μελέτη;

Δημήτρης Μπελντέκος
Θεσσαλονίκη, Πέμπτη 08
Φεβρουαρίου 2018

Class III: Discrete-Subtle Aortic dissection with bulging of the aortic wall



Kalogerakos PD., et al., J Card Surg 2016; 31: 546 - 548

In patients with class 3 dissection, attentive inspection of the proximal ascending aorta by transoesophageal echocardiography can provide unique diagnostic information (subtle intimal discontinuity, circumscribed intramural haematoma, discrete periaortic effusion)

Chirillo F., et al., Heart 2008; 94 :924

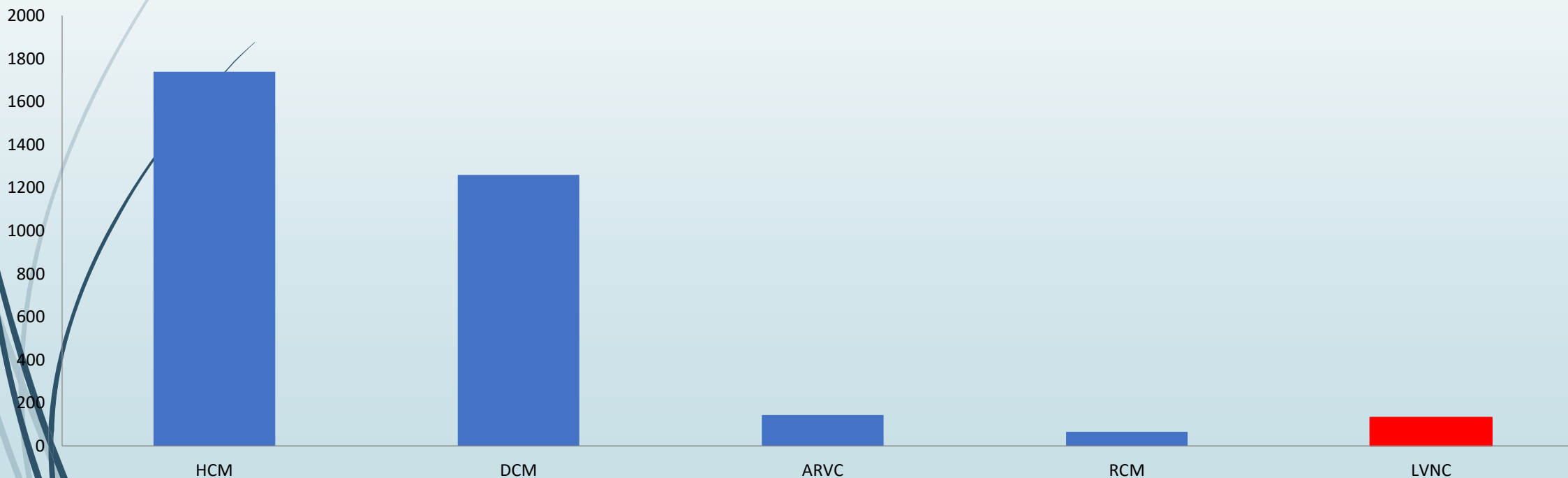
Should an abortive dissection be suspected, it is not unreasonable to proceed with surgery on an urgent surgery in of the potential for future fatal rupture

Kalogerakos PD., et al., J Card Surg 2016; 31: 546 - 548



The Cardiomyopathy Registry of the EURObservational Research Programme of the European Society of Cardiology: baseline data and contemporary management of adult patients with cardiomyopathies

EORP Cardiomyopathies

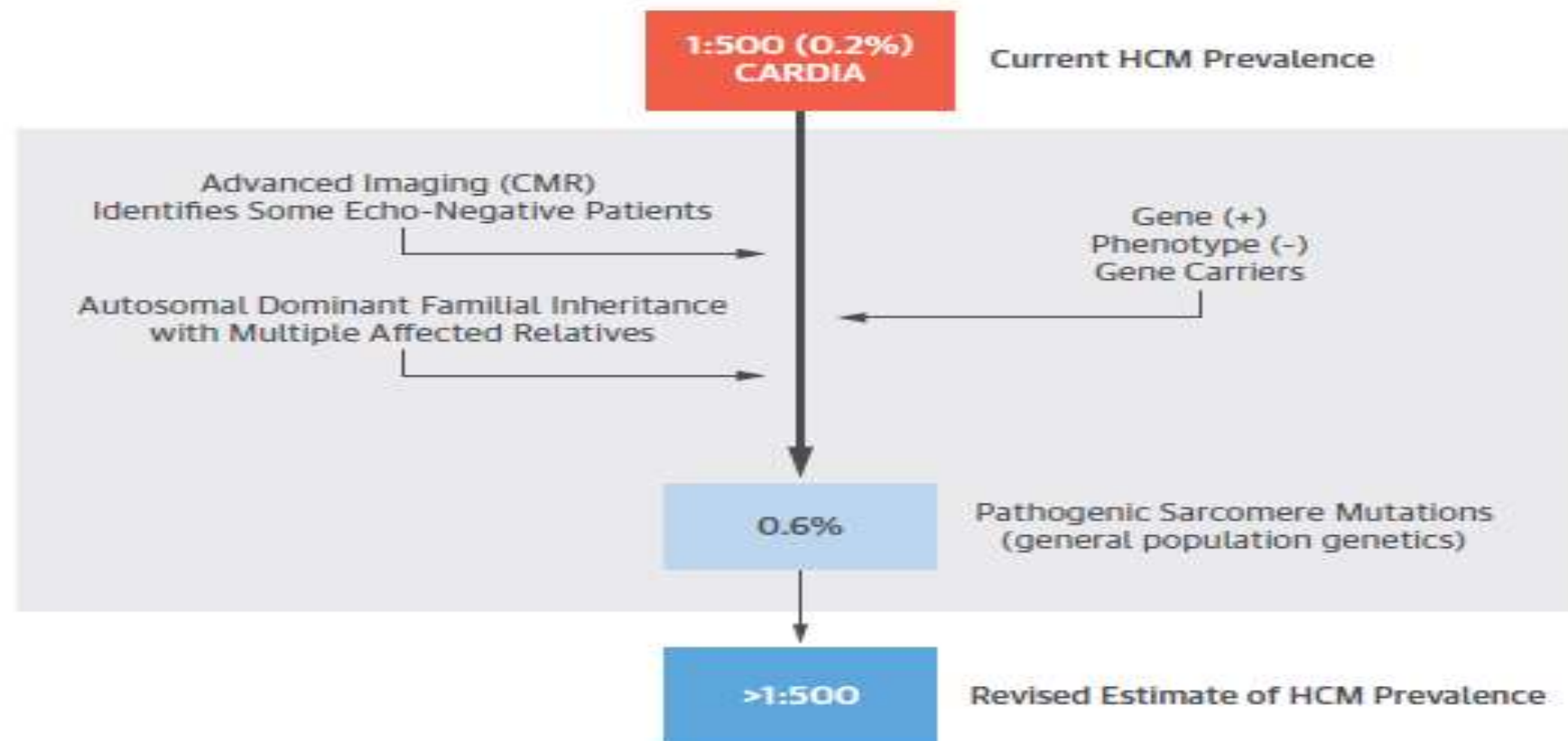




New Perspectives on the Prevalence of Hypertrophic Cardiomyopathy

Christopher Semsarian, MBBS, PhD, MPH,*†‡ Jodie Ingles, GRADDIPGENCOUNS, PhD, MPH,*†‡ Martin S. Maron, MD,§ Barry J. Maron, MD||

CENTRAL ILLUSTRATION Factors Contributing to the Revised Estimate for the Prevalence of HCM



A Discussion of Contemporary Nomenclature, Diagnosis, Imaging, and Management of Patients With Hypertrophic Cardiomyopathy



Barry J. Maron, MD, and Martin S. Maron, MD*

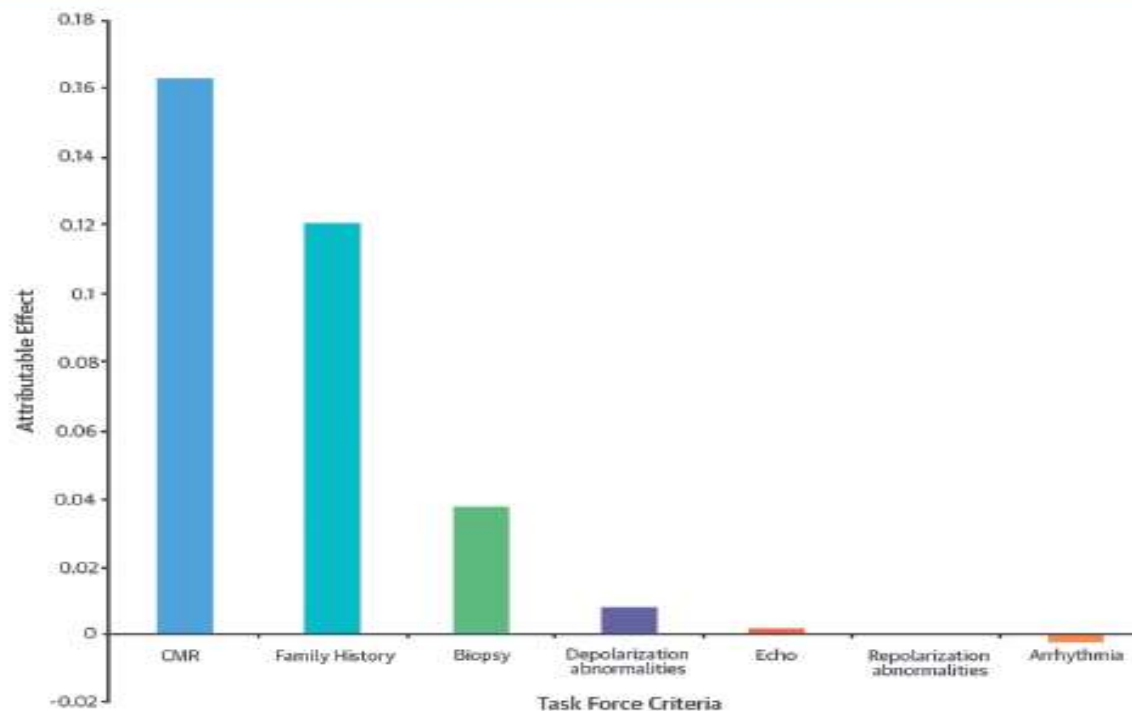
We believe that the designation “concentric” and its distinction from “asymmetric” LV hypertrophy is not useful as a clinical measure in this disease.

Importance of CMR Within the Task Force Criteria for the Diagnosis of ARVC in Children and Adolescents



Yousef Etoom, MD,* Sindu Govindapillai, MD,* Robert Hamilton, MD,* Cedric Manlhiot, BSc,* Shi-Joon Yoo, MD,*† Maryam Farhan, MD,* Samir Sarikouch, MD,‡ Brigitte Peters, MD,§ Brian W. McCrindle, MD,* Lars Grosse-Wortmann, MD*†

Major rTFC to ARVC Diagnosis



Etoom, Y. et al. J Am Coll Cardiol. 2015; 65(10):987-95.

«TZANION»
Hospital 1880

