



19:50 - 20:55

Thursday's Patient Vignettes Potpurri

Moderators: G. Athanassopoulos, K. Lampropoulos, S. Adamopoulos

Panel: S. Fragoulis, S. Kyrzopoulos, M. Koutelou, A. Dimopoulos, L. Poulimenos, E. Sanidas

Management of a patient with Pulmonary Thromboembolic Disease


E. Demerouti

Case presentation

P. Karyofyllis

Therapeutic challenges & Treatment

Conflict of interests




NAME OF COMPANIES WITH WHICH RELATIONSHIP EXISTS

Actelion Pharmaceuticals Ltd
Janssen
Demo Hellas
Elpen
Galenica
Menarini
MSD Hellas, Merck and Sharp

NAME OF RELATIONSHIP

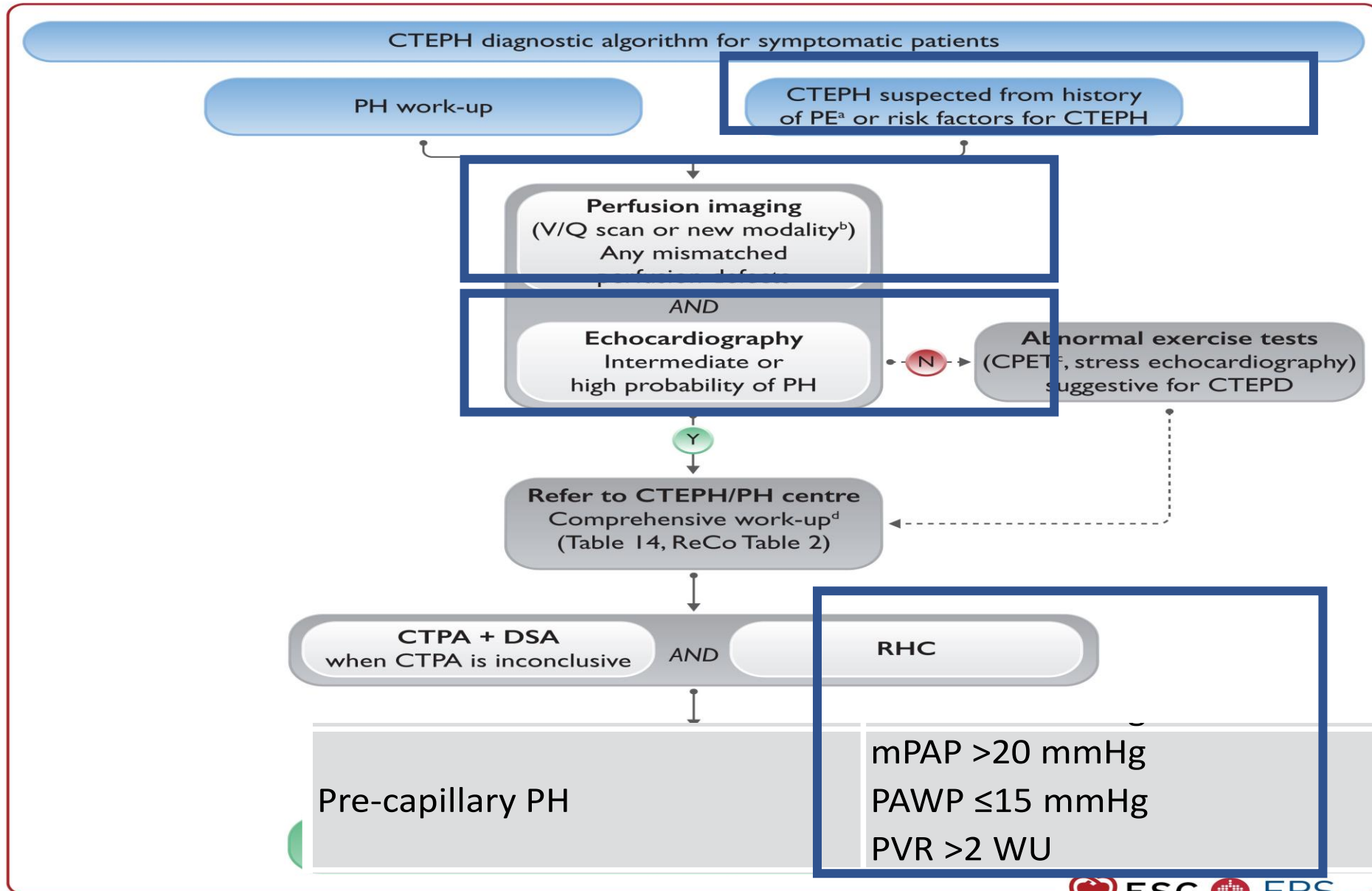

Consultant
Grants
Advisory Board Member

Pathophysiology of CTEPH



- Rare complication of acute pulmonary embolism
- Characterized by fibro-thrombotic obstructions of large pulmonary arteries combined with small vessel arteriopathy^[a]
- Poor prognosis if not treated^[b]
- Survival rates at 5 years^[c]
 - 30% in patients w/mPAP >40 mmHg
 - 10% in patients w/mPAP >50 mmHg
- However, a number of treatment options are now available
- The management of CTEPH has advanced in recent years

Diagnostic strategy in chronic thrombo-embolic pulmonary hypertension

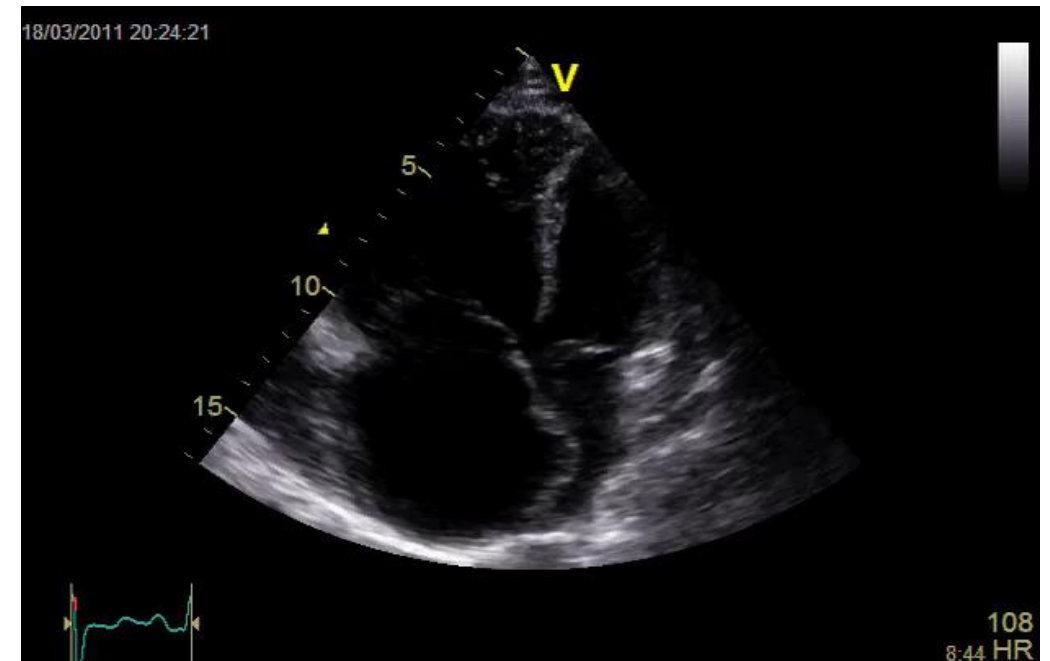
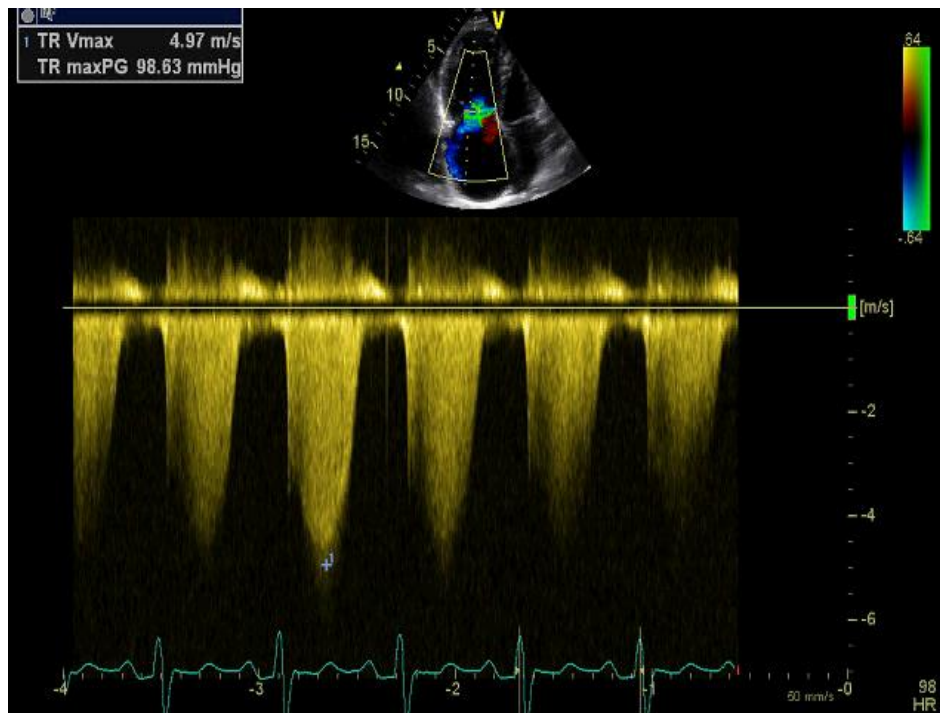

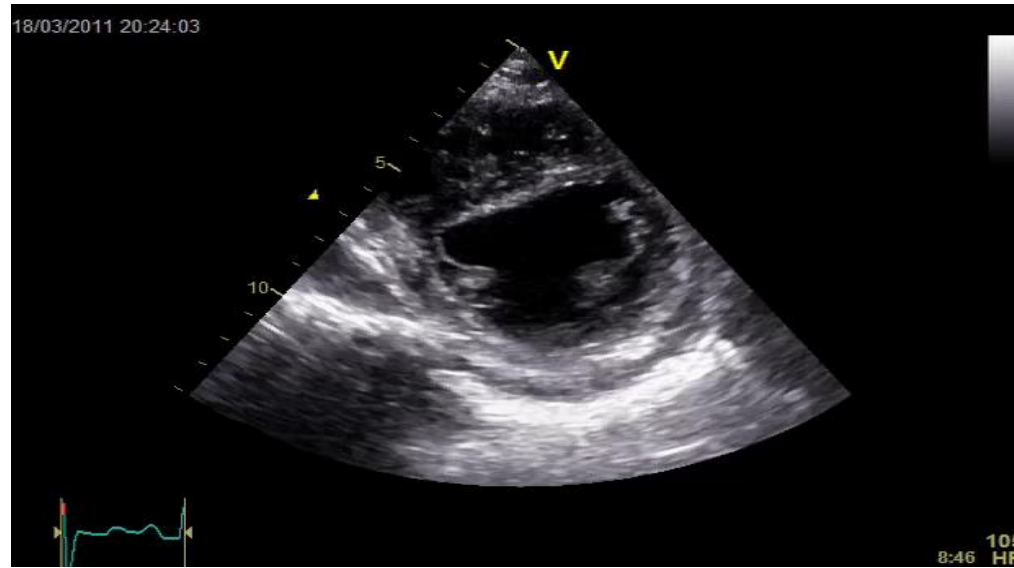


Medical history




- Male born in 10/1982
- APS, recurrent episodes of thrombosis
- Pulmonary embolism 2007
- Progressively worsening dyspnea WHO III since 09/2010
- spO2 (rest) 98%

Diagnostic evaluation



2010

RHC, Diagnosis confirmation



RHC

2010

RAP	14 mmHg,
mPAP	63 mmHg
PAWP	9 mmHg
CI	2,2 l/min/m ²
PVR	14,2 WU

Medical treatment:

inhaled iloprost 20 μ x6

bosentan 125mg x2

Sildenafil 20mgx3


furosemide 40mg x1

acenocoumarol

NT-proBNP 4153 pg/ml

Referral for PEA

2011: operated in Paris

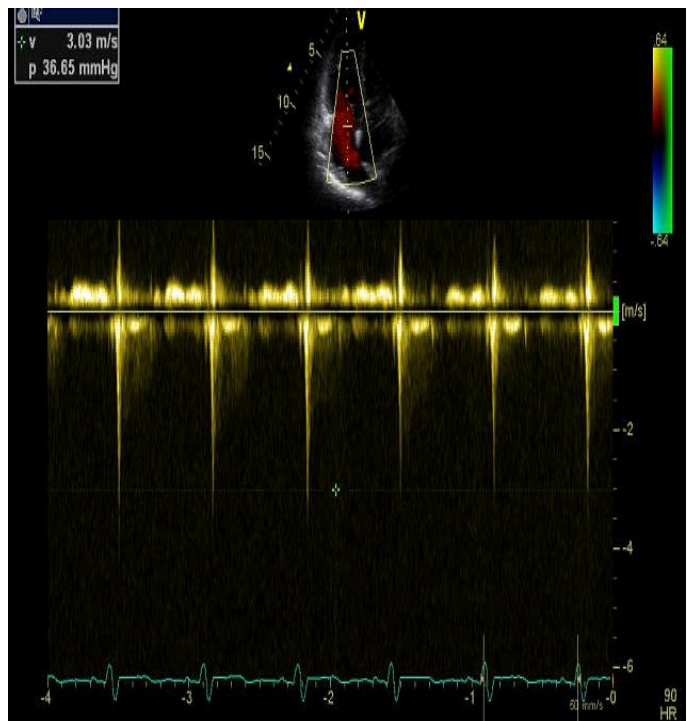
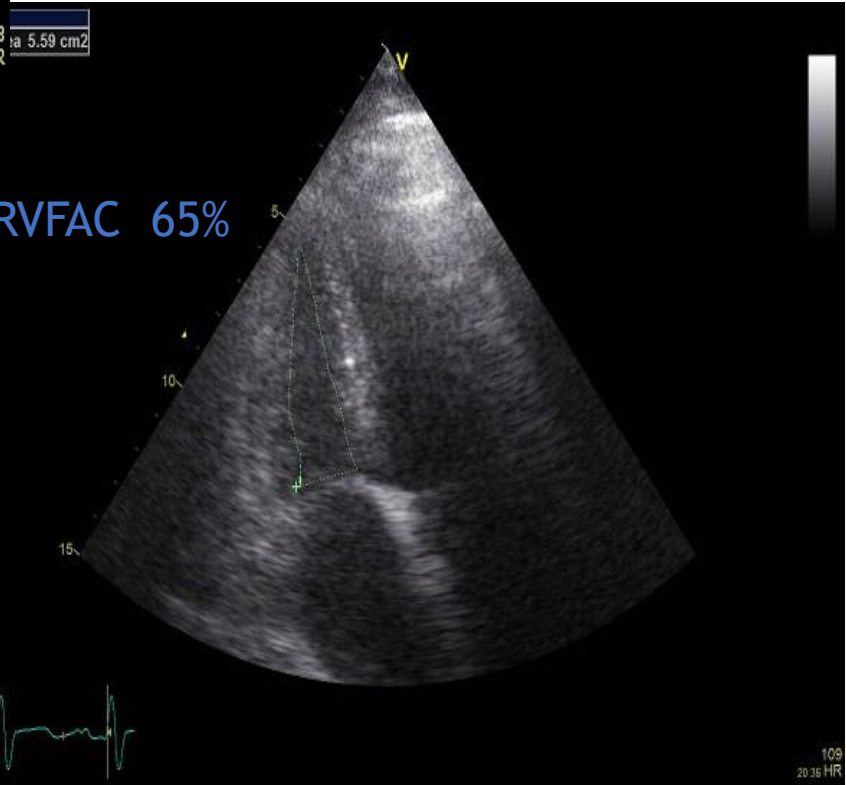
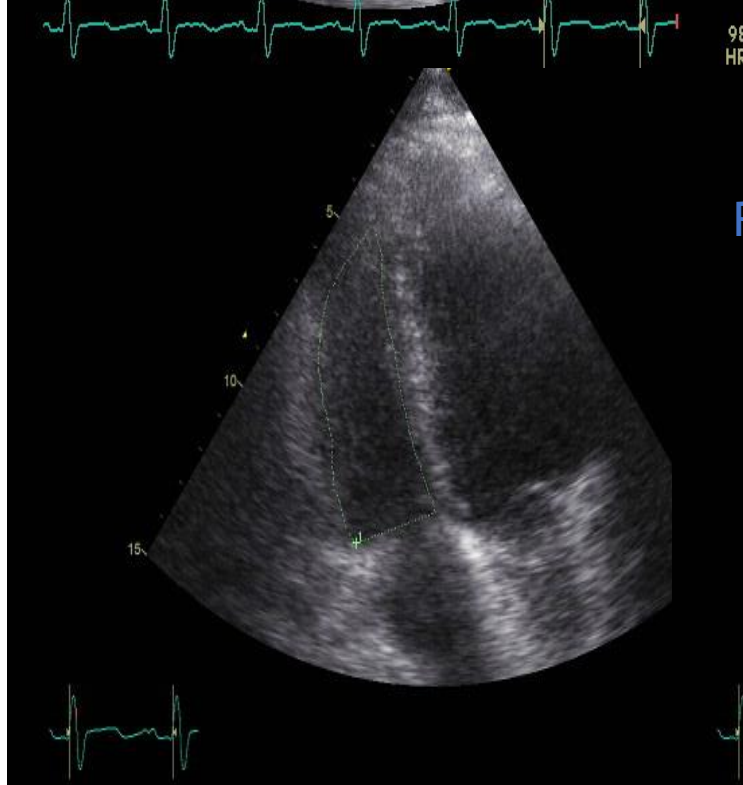
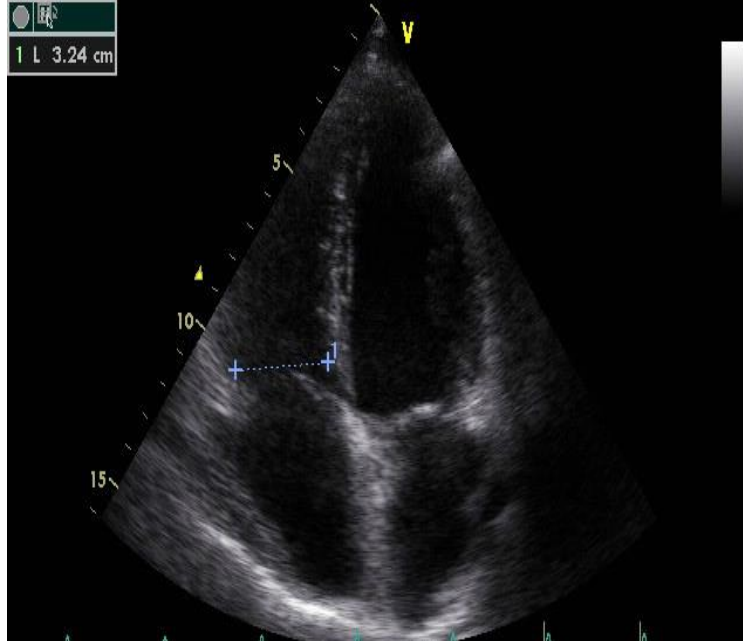


5 years later


Under anticoagulation therapy

PA mean 23mmHg

PVR 2,6 WU




Key Principles in CTEPH Management



Accurate diagnosis

Lifelong
anticoagulation
therapy unless
contraindicated

All patients with
CTEPH should be
referred for
operability
assessment for
pulmonary
endarterectomy
(PEA)




ORIGINAL ARTICLE - HYPERTENSION

Dynamic Risk Stratification of Patient Long-Term Outcome After Pulmonary Endarterectomy

Results From the United Kingdom National Cohort

- Up to 51% fail to manifest a $mPAP < 25 \text{ mmHg}$
- $mPAP > 38 \text{ mmHg}$ or $PVR > 425 \text{ dyn s cm}^{-5}$ after PEA -> worse prognosis
- 17% of CTEPH patients developed recurrent/persistent PH

Follow up after PEA



08/2011 - 09/2018

WITHOUT SYMPTOMS,

TTE NORMAL, RHC (2Y) NORMAL HAEMODYNAMICS

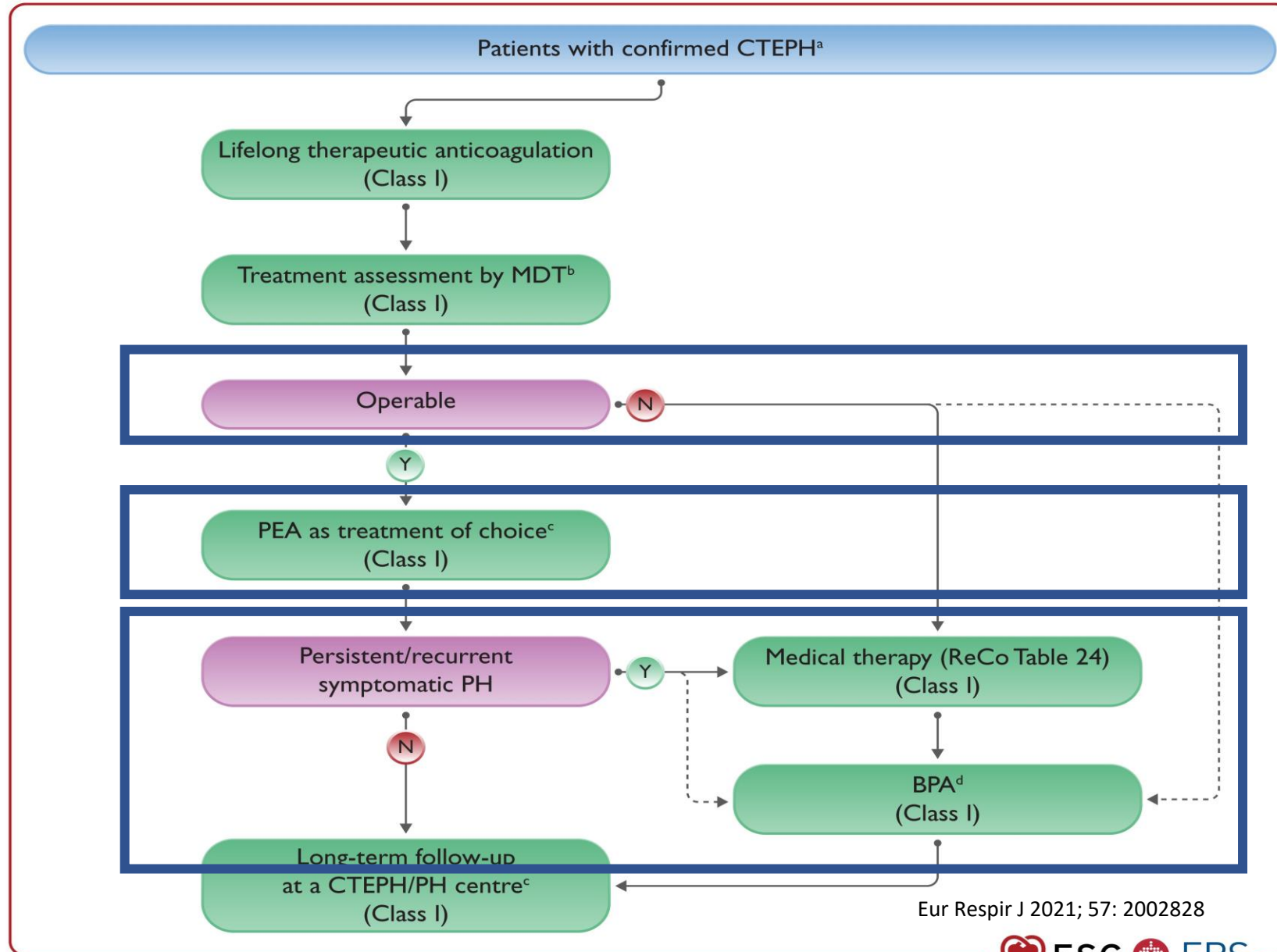

RHC sept '18: PVR 3.1WU, C.I. 2.9 l/min/m², mPAP 24mmHg

- 2019: new episodes of dyspnea and chest pain
- Lung scintigraphy: segmental and subsegmental perfusion deficits in LL, subsegmental deficits in RL

RHC 05/2019

RA 4mmHg, PA 51/20/32 (71.3%), PVR 4,8

Management strategy in CTEPH



Thank you
for your
attention