

Refractory Angina

PCI, CABG, Medications, PCIs...
then what???

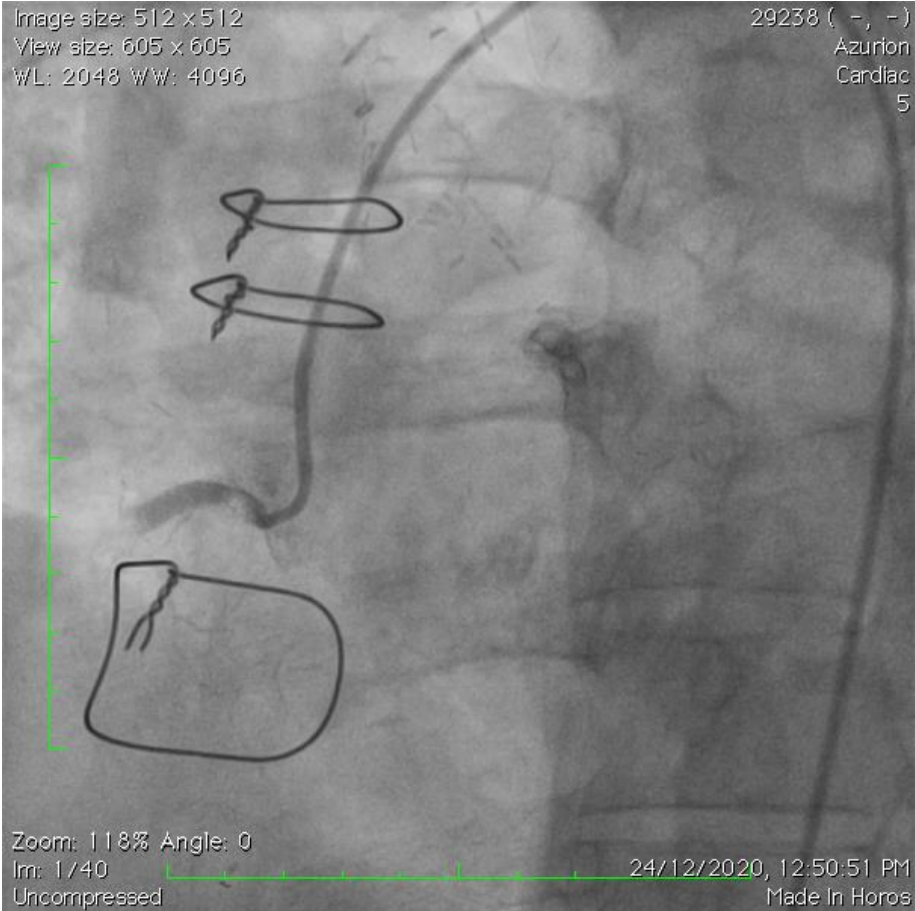
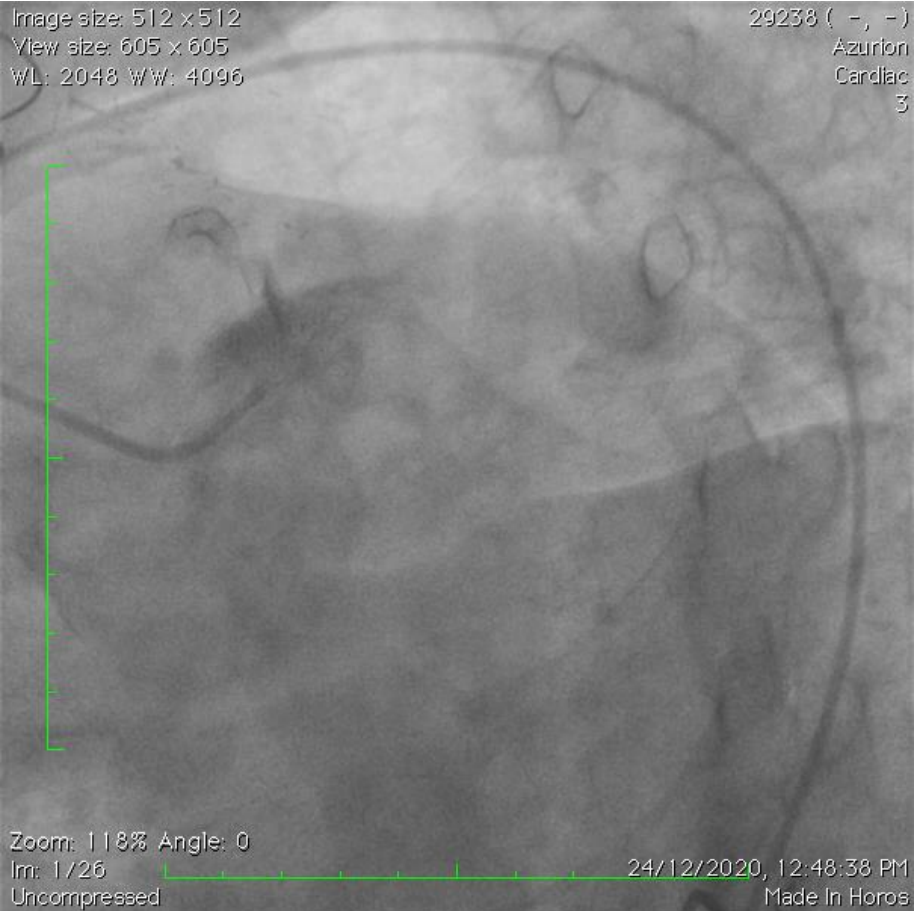Nektarios Pilatis, MD
Interventional Cardiology
Chief, E' Cardiology Dpt
Henry Dunant Hospital Center
April 11, 2024

**I have no conflict of interest to
disclose**

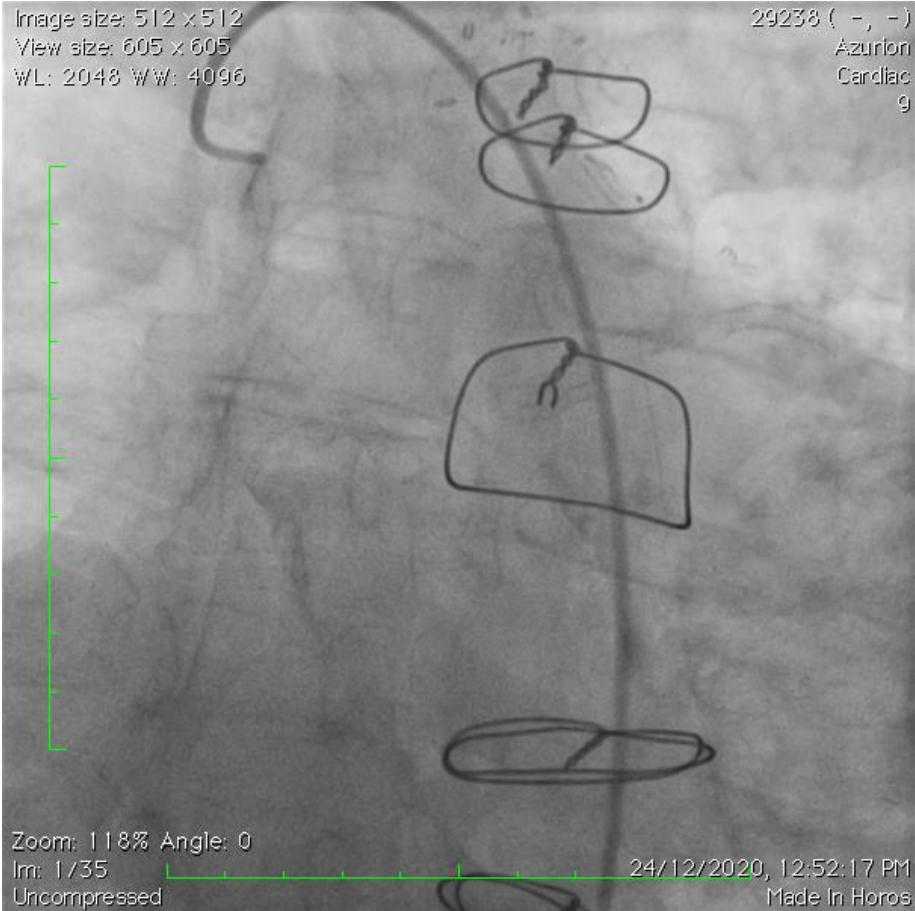
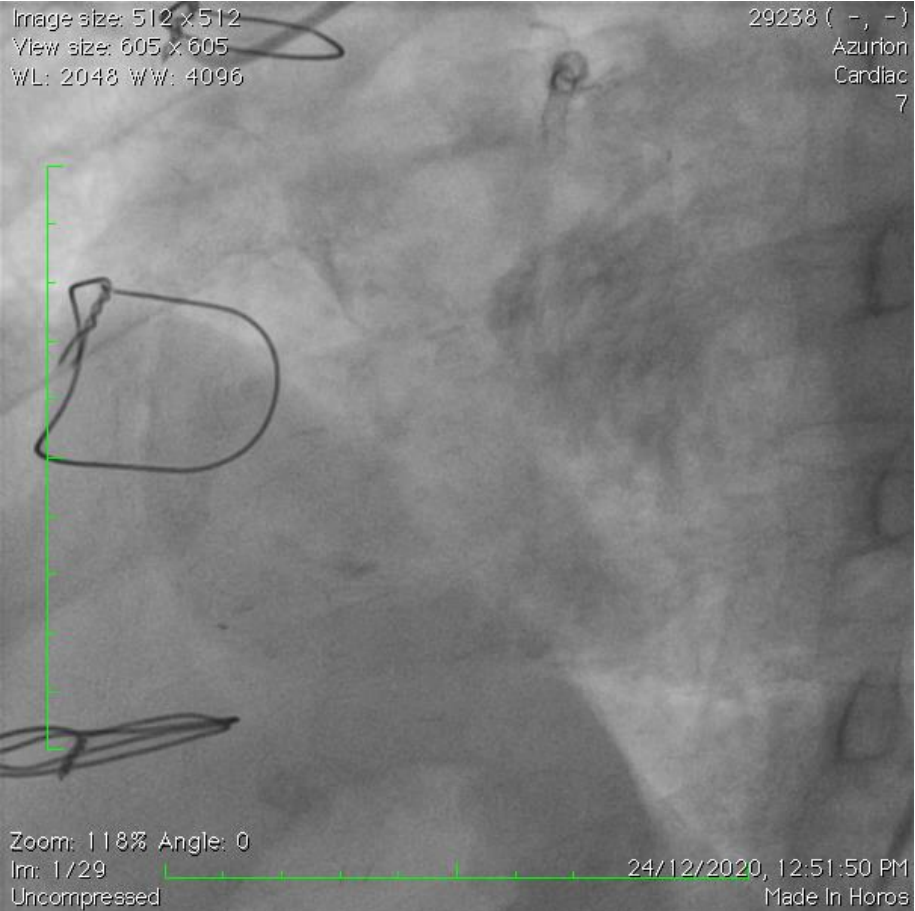
Case Presentation

- 62 year-old man with severe angina CCS class IV and orthopnea starting 4 months prior to presentation
- PMH of
 - Old anterior MI with stent prox-mid LAD and prox RCA (41 year-old)
 - CABG x 3 (45 year-old)
 - CKD, on HD (51 year-old)
 - **Occluded stents of LAD, RCA, RI**
 - PCI-stent of LIMA ostium x2 (4 years and 6 months ago)
 - **PCI-stent of RI x 2** (3 years and 6 months ago for occlusion)
 - PAF
 - PPM-Defibrillator (61 year-old)
- **Medications:** Clopidogrel, ASA, Verapamil, Nitrates, Amiodarone, atorvast-ezetimibe, Alprazolam, anti-depressant
- **ECG:** SR=60, 1o AVB, RBBB, LAFB, old anterior MI
- **Echo(TTE-TEE)** showed
 - **LVD=57/40**, EF=45%, antero-apical akinesis
 - LA=44 mm, mild-AS (AVA=1.2 cm², Vmax=2.4)
 - **normal RV fx**
 - RVSP was 25 mmHg.
- **Hb=11,9 /dl**

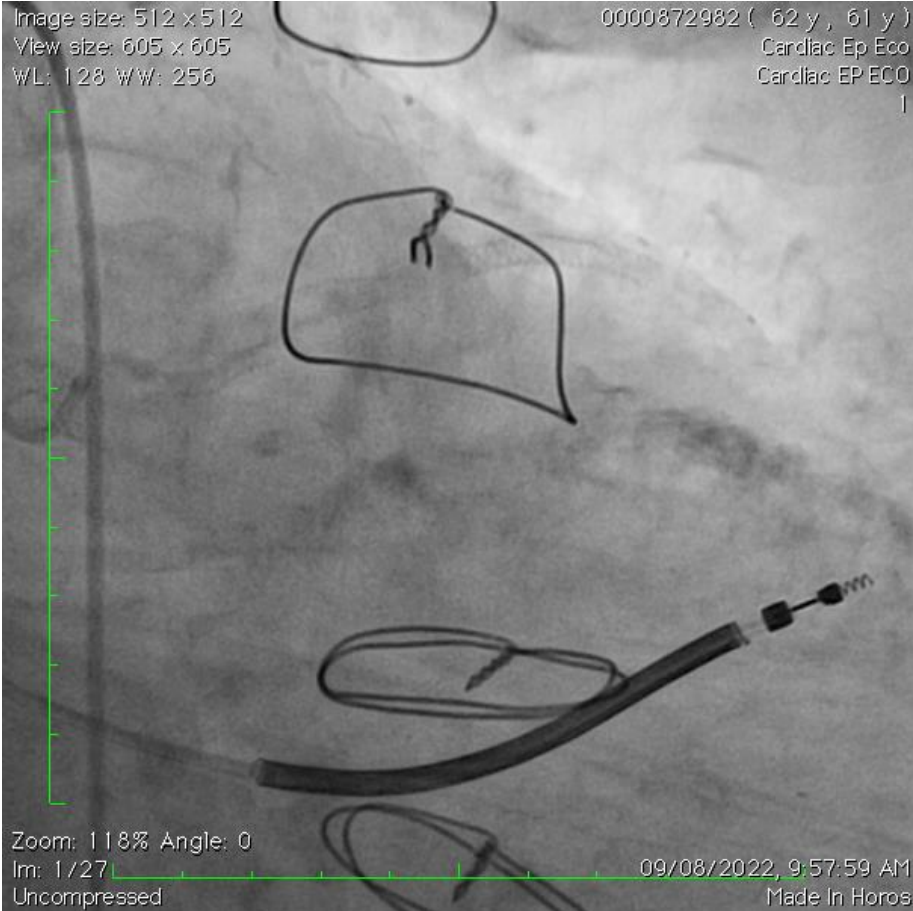
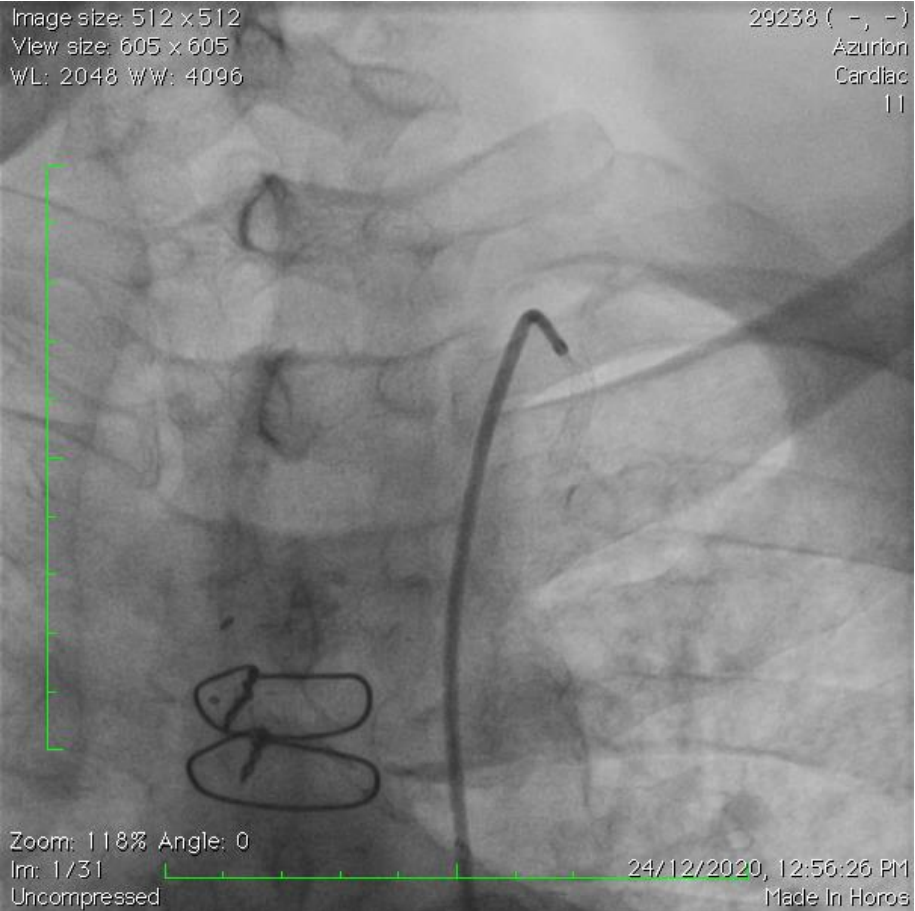
Angiogram 2 years ago



Angiogram 2 years ago



Angiogram 2 years ago and 4 months prior



Refractory angina CCS class IV and orthopnea

- Medications

- Nitrates
- Verapamil
- Beta blockers
- Ranolazine
- Ivabradine

- Multiple hospital visits
- Four cardiac cath in one year for rest angina and troponin elevation

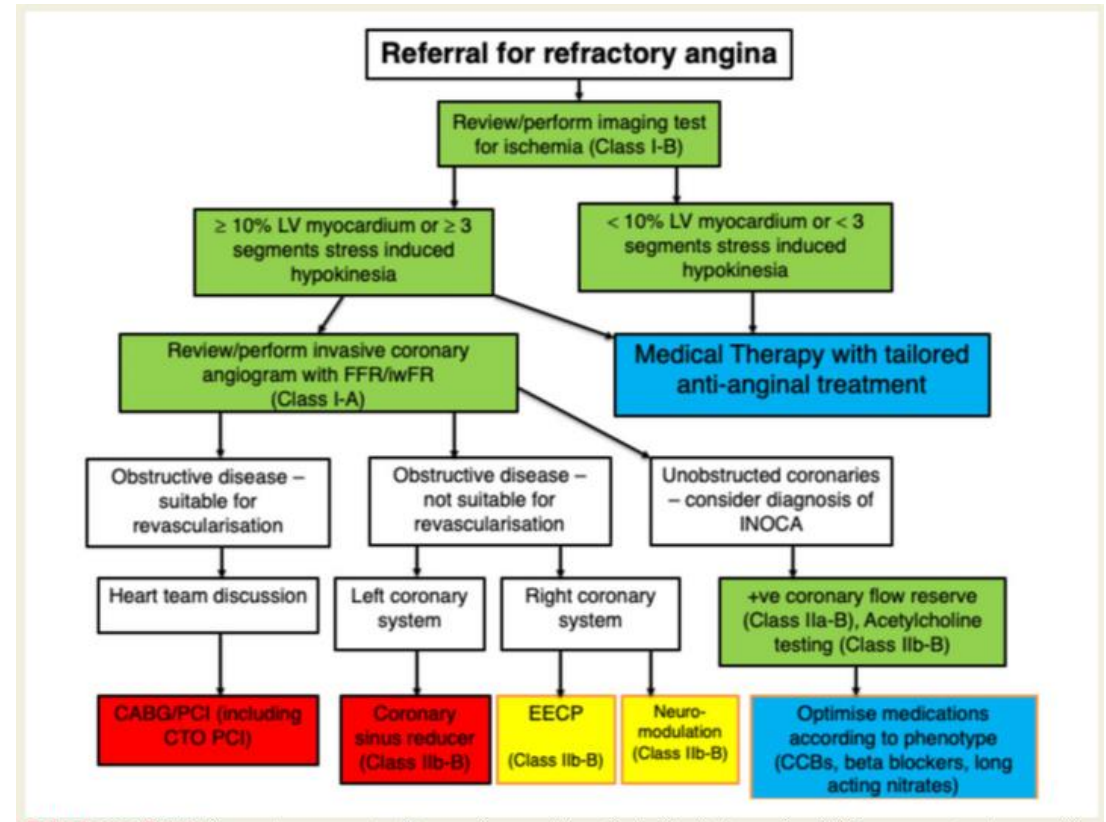
And now, what ???

- Radiation therapy for recurrent restenosis
- Cardiac rehabilitation
- Enhanced external counterpulsation
- Coronary sinus occlusion
- Extracorporeal shockwave myocardial revascularization
- Spinal cord stimulation
- Pain-relieving drugs
- Angiogenetic therapies
- Stem cells therapy


Management of refractory angina: an update

Allan Davies^{1,2}, Kim Fox^{1,2}, Alfredo R. Galassi³, Shmuel Banai^{4,5},
Seppo Ylä-Herttuala⁶, and Thomas F. Lüscher^{1,2,7*}

- Radiation therapy for recurrent restenosis
- Cardiac rehabilitation
- Enhanced external counterpulsation
- **Coronary sinus occlusion**
- Extracorporeal shockwave myocardial revascularization
- Spinal cord stimulation
- Pain-relieving drugs
- Angiogenetic therapies
- Stem cells therapy



Coronary Sinus REDUCER

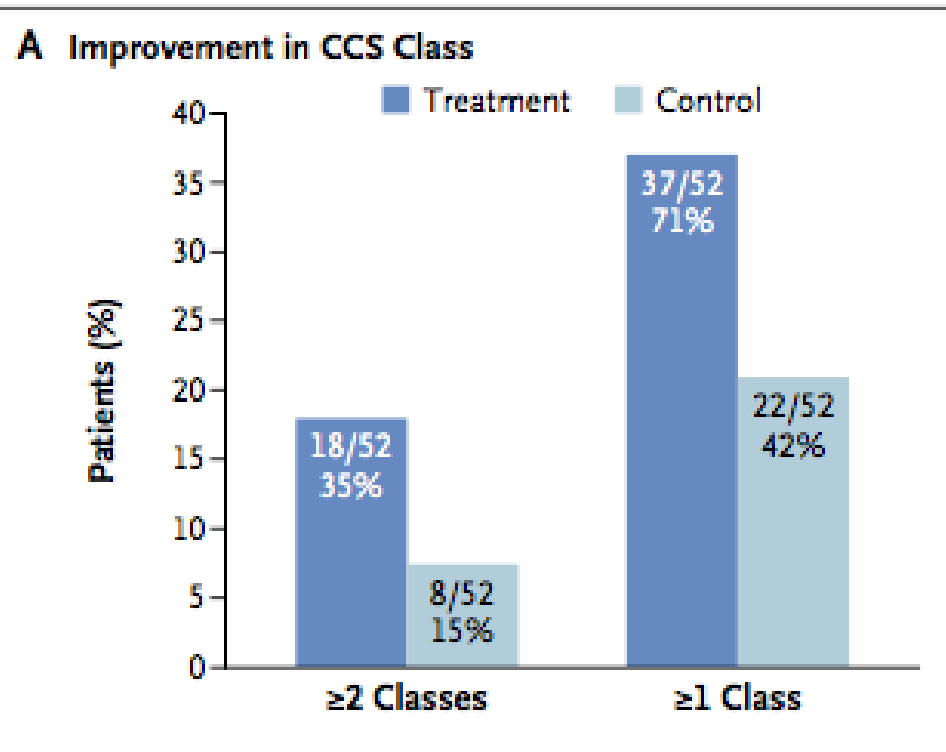


ORIGINAL ARTICLE

Efficacy of a Device to Narrow the Coronary Sinus in Refractory Angina

Stefan Verheye, M.D., Ph.D., E. Marc Jolicœur, M.D., Miles W. Behan, M.D.,

CSR Improved angina



COSIRA trial, 2015, 104 pts

Coronary sinus reducer for the treatment of refractory angina (ORBITA-COSMIC): a randomised, placebo-controlled trial

Michael J Foley, Christopher A Rajkumar, Fiyyaz Ahmed-Jushuf, Florentina A Simader, Shayna Chotai, Rachel H Pathimagaraj,

CSR Improved angina, no myocardial perfusion

	CSR group (n=25)	Placebo group (n=26)
Death	0	0
Myocardial infarction	0	0
Stroke	0	0
Bleeding	0	0
CSR embolisation	2 (8%)	0
Inability to deploy CSR	1 (4%)	0

Data are number of events (%). CSR=coronary sinus reducer.

Table 5: Adverse events

	Odds ratio of transition to fewer angina episodes each day with CSR vs placebo	Probability of benefit with CSR vs placebo
Day 2 of follow-up	1.01 (0.80-1.28)	53.1%
Day 70 of follow-up	1.15 (1.00-1.30)	98.1%
Day 182 of follow-up	1.40 (1.08-1.83)	99.4%

Data are odds ratio (95% credible interval) or percentage. Results are reported for both the start of the follow-up period (day 2), day 70, and the end (day 182). CSR=coronary sinus reducer.

Lancet, April 8, 2024 (51 pts)

Coronary Sinus Reducer for the Treatment of Chronic Refractory Angina: Will This Challenge the Treatment of Coronary Chronic Total Occlusions?

Giovanni Maria Vescovo¹ · Carlo Zivelonghi¹ · Michele Bellamoli² · Paul Vermeersch¹ · Stefan Verheye¹ · Pierfrancesco Agostoni¹ 

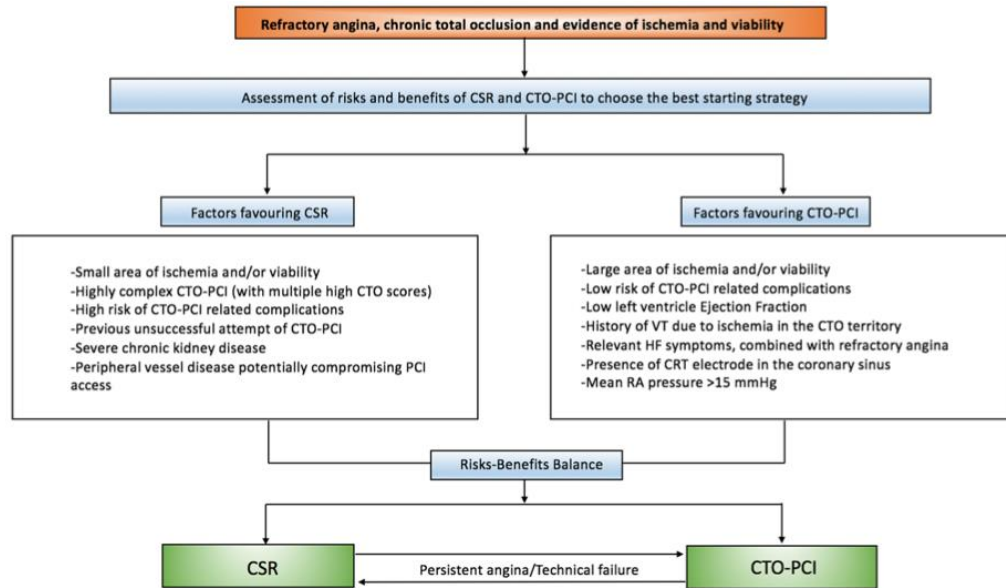



Fig. 2 Evaluation of clinical and technical features to select the first therapeutic option in patients with chronic total occlusion and refractory angina. CTO-PCI chronic total occlusion percutaneous coronary

intervention, VT ventricular tachycardia, HF heart failure, CRT cardiac resynchronization therapy, RA right atrial, CSR Coronary Sinus Reducer

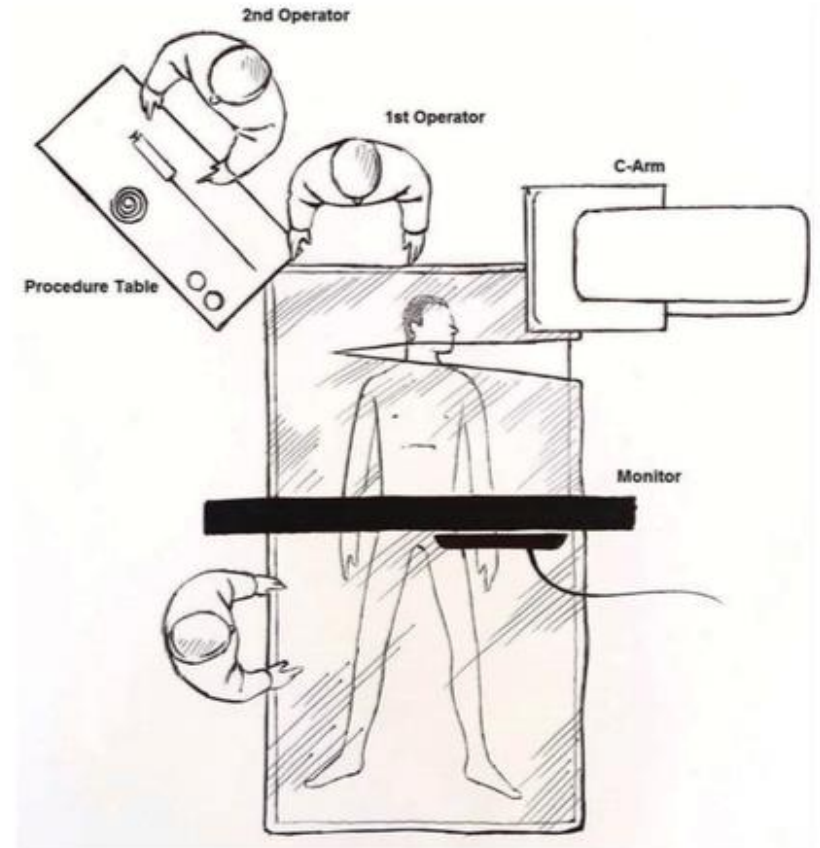
Zivelonghi C, Verheye S, Timmers L, van Kuijk JP, Giannini F, Dekker M, et al. **Efficacy of Coronary Sinus Reducer in patients with non-revascularized chronic total occlusions. Am J Cardiol.** 2020;126:1–7 This recent retrospective study shows for the first time the efficacy of the device among patients with chronic total occlusions. The authors provide also pathophysiological considerations, based on previous experimental studies, to explain the greater benefits of Coronary Sinus Reducer in this subgroup of patients.

Coronary Sinus REDUCER

In preparing the balloon, it is important not to exceed a 25% contrast: 75% saline ratio in order to facilitate balloon deflation and retrieval



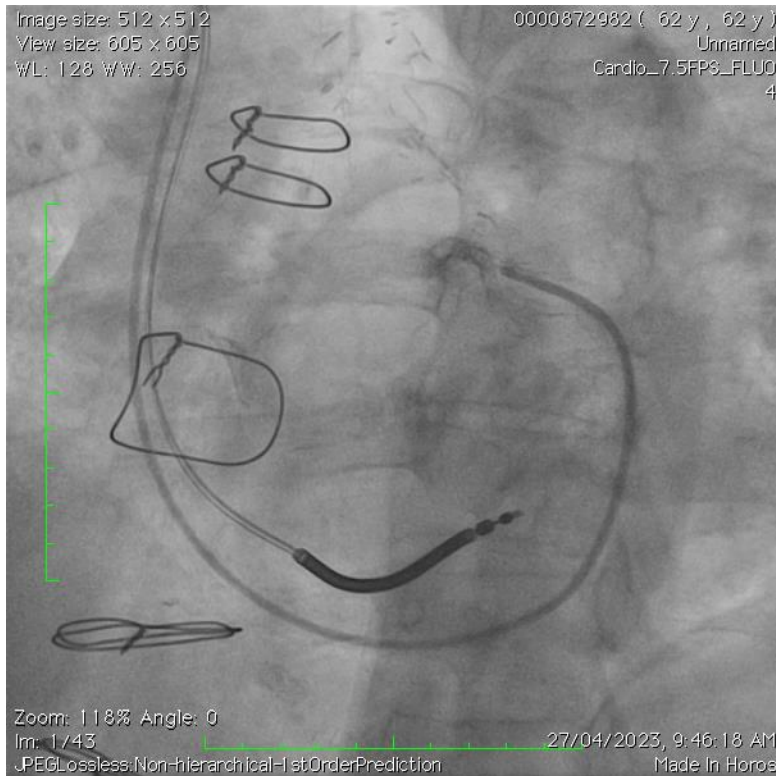
**Cath Lab setup
LAO 30° view**



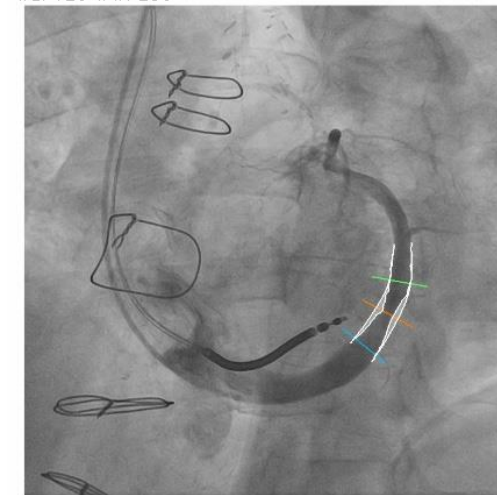
Procedure of CSR implantation 1

MPA2 5 Fr, RA pressure <15 mmHg

CS diameter calculation



Quantitative Coronary Analysis



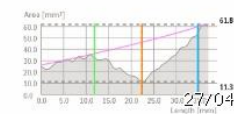
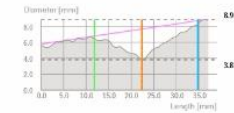
0000872982 (62 y , 62 y)
Unnamed
4

Stenosis Length **22.90 mm**
% Stenosis Diameter **50.50 %**

Minimum Lesion Diameter (MLD) **3.80 mm**
User Defined MLD **3.80 mm**
Proximal Diameter **6.44 mm**
Distal Diameter **8.29 mm**
Expected Diameter **7.67 mm**
Maximum Diameter **8.87 mm**

Stenosis Area **11.32 mm²**
% Stenosis Area **75.50 %**
Plaque Area **43.10 mm²**
Stenosis Symmetry **0.91**

Contour correction **None**
Calibration object **Catheter 6 Fr**
Calibration factor **0.157 mm/px**
Series **4**
Image **23**



Zoom: 61% Angle: 0
Im: 1/1

.PEGLossless:Non-hierarchical-IstOrderPrediction

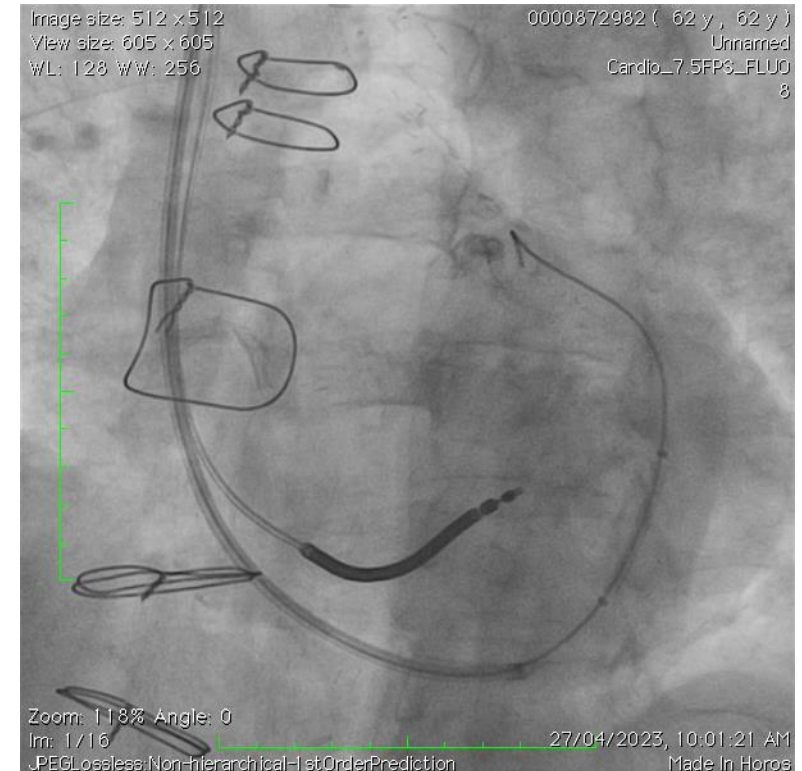
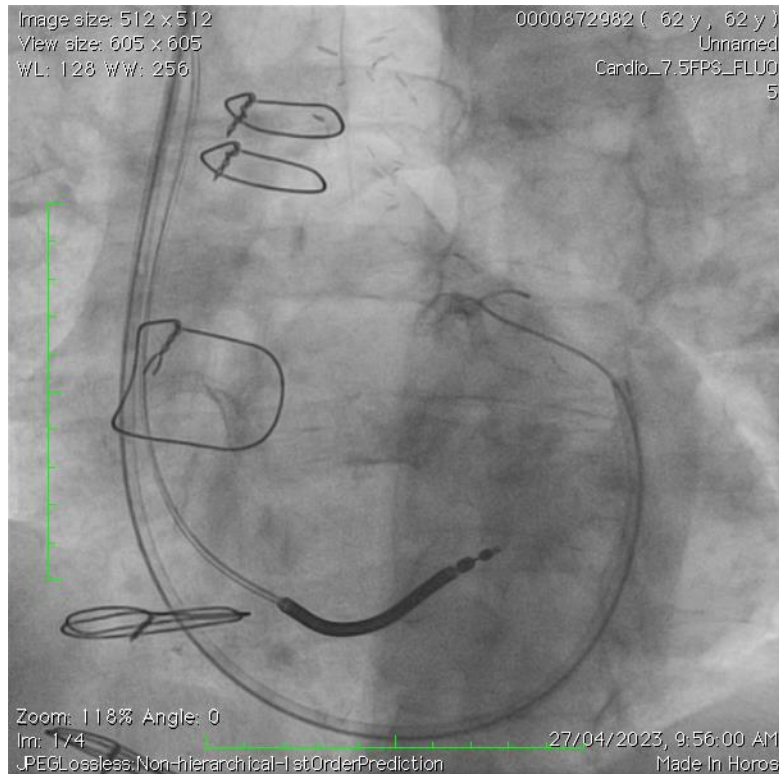
27/04/2023, 9:50:57 AM

Made In Horos

Procedure of CSR implantation 2

0,35 J wire, 9 Fr guide-catheter (mother-in-child)

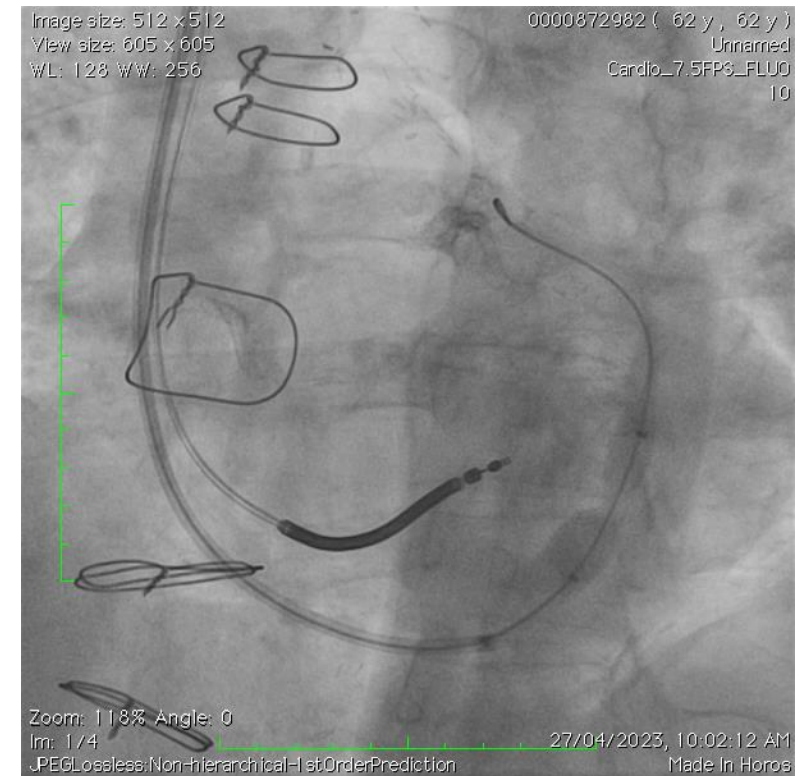
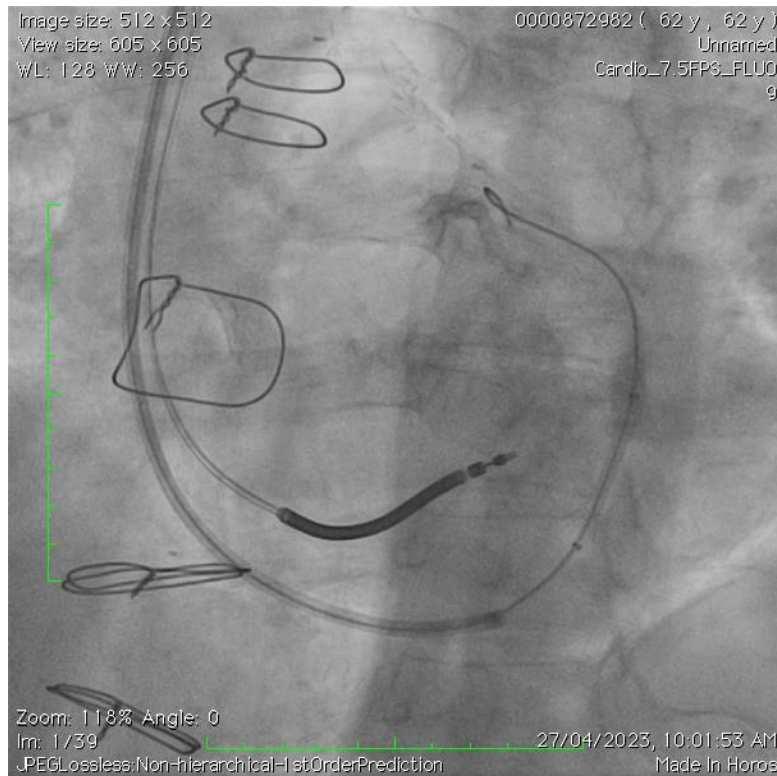
Device implantation is usually 1.5–3-cm distal to the coronary sinus ostium, where the vessel diameter is approximately 7–14 mm



Procedure of CSR implantation 3

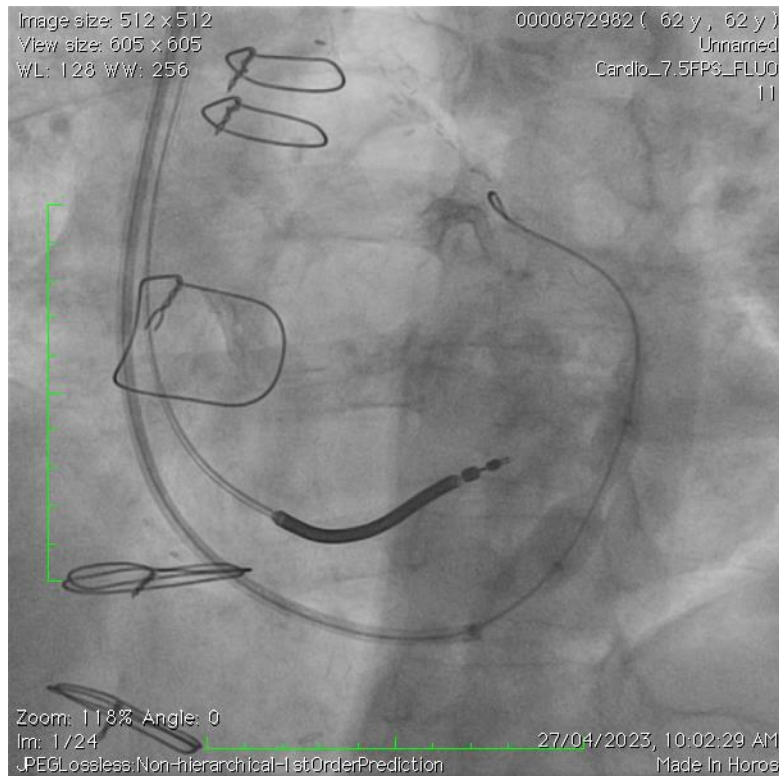
The Reducer is deployed by inflating the delivery balloon at 4–6 atmospheres for at least 60 s.

Importantly, it is imperative to oversize the device relative to the sinus by 10–20%.

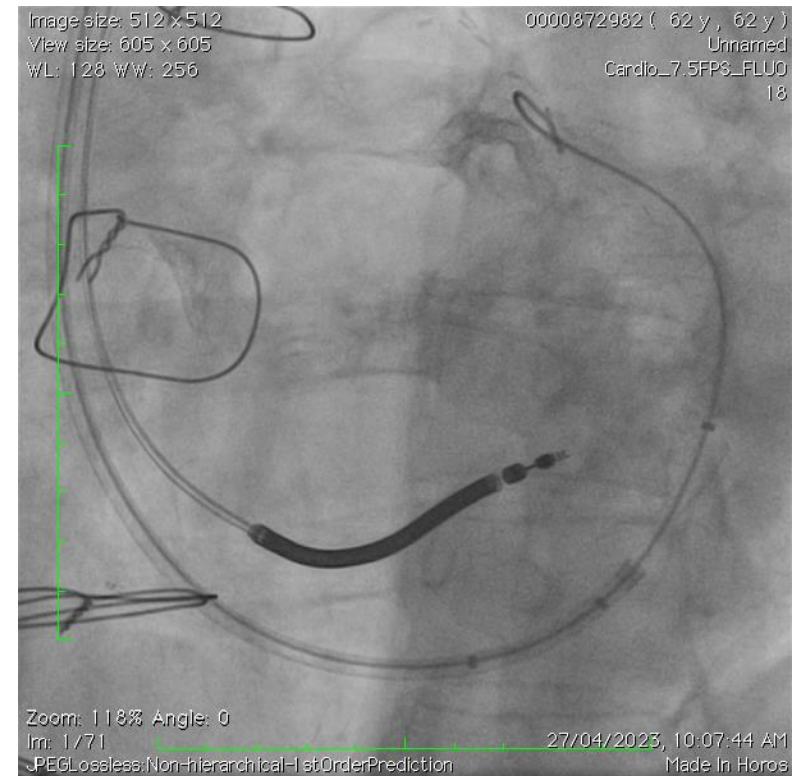


Procedure of CSR implantation 4

Balloon inflation

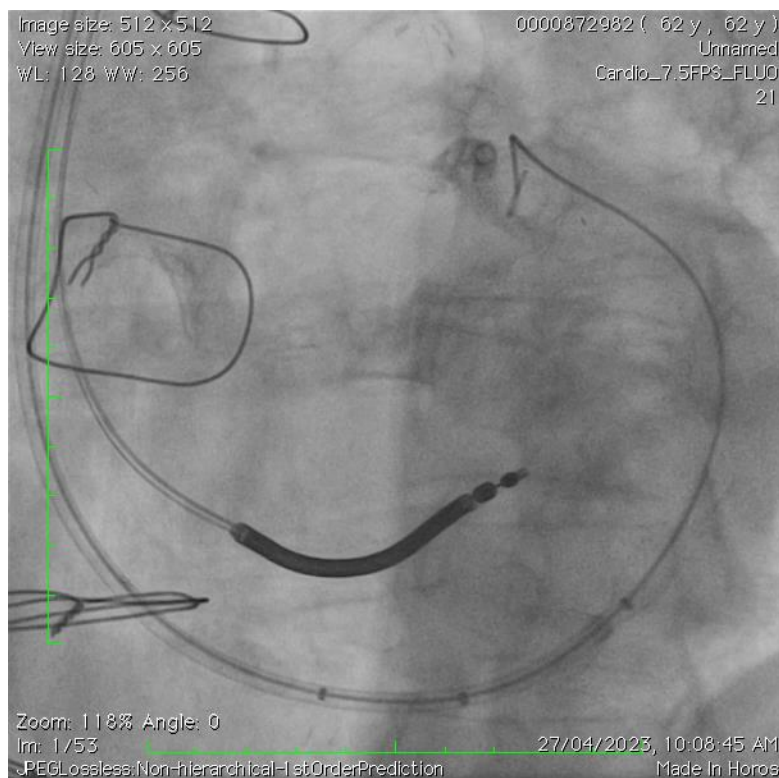

Balloon (and stent... retrieval)

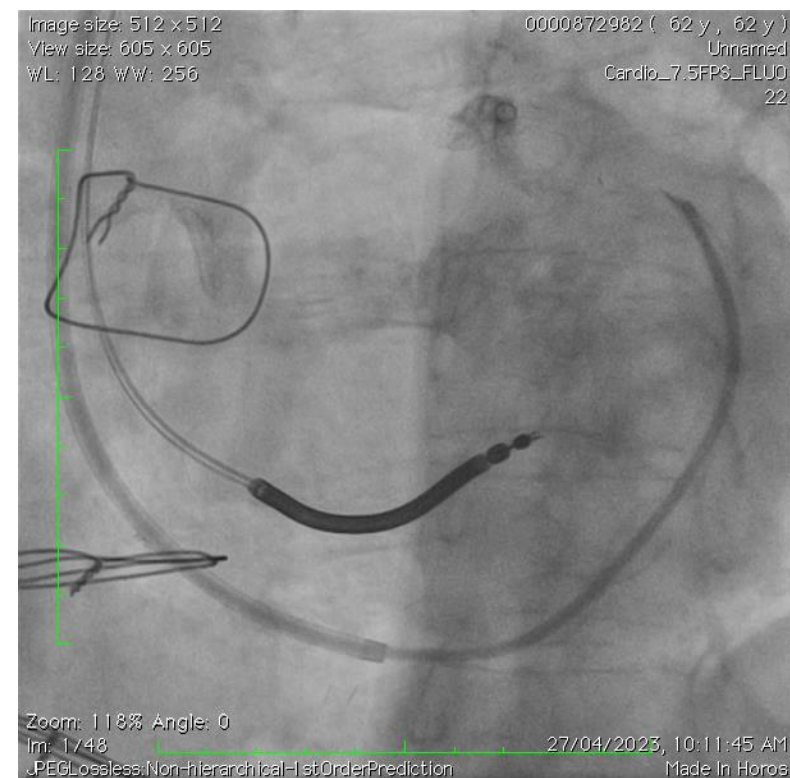


Procedure of CSR implantation 5

Final balloon retrieval

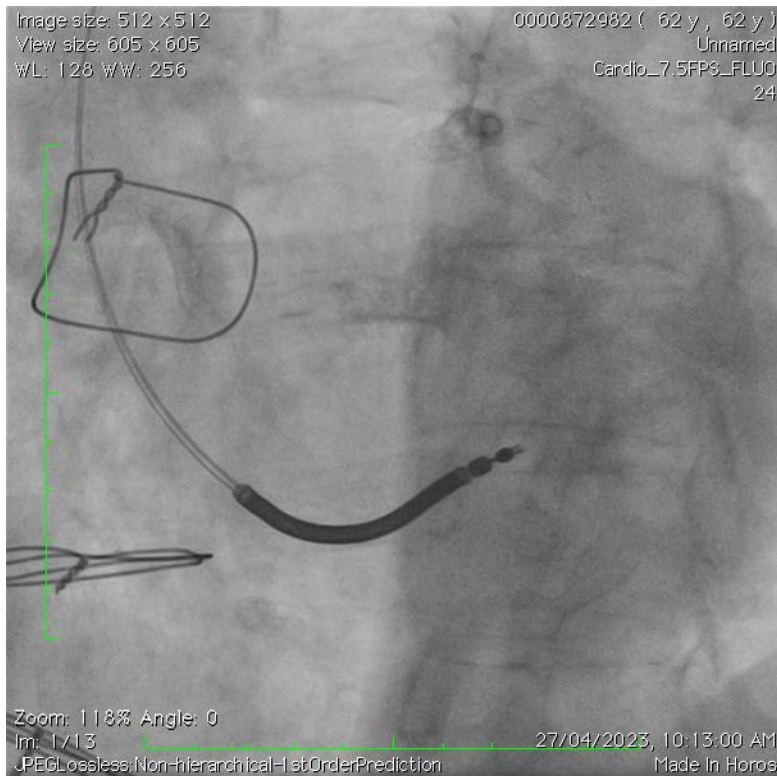


Stent in proximal CS



Procedure of CSR implantation 6

Stent is stable



At present, accumulating evidence supports the clinical benefit of the Reducer in **alleviating symptoms of angina in 70–80%** of patients with obstructive CAD of **of the left coronary system** who are not candidates for revascularization

One year later

- Patient has minimal angina
- His quality of life improved dramatically
- He is gardening
- He quit anti-depressant meds

COSIRA-II trial

- **Randomized, placebo-controlled**
 - To demonstrate the safety and effectiveness of the Reducer system for treatment of patients with refractory angina pectoris treated with maximally tolerated guideline-directed medical therapy who demonstrate objective evidence of reversible myocardial ischemia in the distribution of the **left** coronary artery and who are deemed unsuitable for revascularization.
- **A non-randomized single-arm**
 - will further assess the safety and effectiveness of the Neovasc Reducer System in selected subjects with reversible myocardial ischemia
 - in the distribution of the **right** coronary artery and who are deemed unsuitable for revascularization,
 - subjects with reversible myocardial ischemia **without** documented obstructive coronary disease and
 - subjects who cannot complete an exercise tolerance test due to an **above-the-ankle amputation**.

Thank you